

8-31-2023

Cone-Beam Computed Tomography Assessment of Morphologic and Anatomic Changes of the Nasopalatine Canal: Cross-Sectional Study

Hümeyra Tercanlı

Department of Oral and Maxillofacial Radiology, Akdeniz University, Antalya, Turkey,
ysl_hymr25@hotmail.com

Ayşe Taş

Department of Oral and Maxillofacial Radiology, Medipol, University, İstanbul, Turkey,
dt.ays.tas@gmail.com

Gamze Coşan Ata

Department of Oral and Maxillofacial Radiology, Çanakkale Onsekiz Mart University, Antalya Turkey,
gamze.cosan40@gmail.com

Follow this and additional works at: <https://scholarhub.ui.ac.id/jdi>



Part of the [Oral and Maxillofacial Surgery Commons](#)

Recommended Citation

Tercanlı, H., Taş, A., & Coşan Ata, G. Cone-Beam Computed Tomography Assessment of Morphologic and Anatomic Changes of the Nasopalatine Canal: Cross-Sectional Study. *J Dent Indones.* 2023;30(2): 128-135

This Article is brought to you for free and open access by the Faculty of Dentistry at UI Scholars Hub. It has been accepted for inclusion in Journal of Dentistry Indonesia by an authorized editor of UI Scholars Hub.

ORIGINAL ARTICLE

Cone-Beam Computed Tomography Assessment of Morphologic and Anatomic Changes of the Nasopalatine Canal: Cross-Sectional Study

Hümeyra Tercanli¹, Ayşe Taş², Gamze Coşan Ata^{3*}

¹*Department of Oral and Maxillofacial Radiology, Akdeniz University, Antalya, Turkey*

²*Department of Oral and Maxillofacial Radiology, Medipol, University, İstanbul, Turkey*

³*Department of Oral and Maxillofacial Radiology, Çanakkale Onsekiz Mart University, Antalya Turkey*

*Correspondence e-mail to: gamze.cosan40@gmail.com

ABSTRACT

Objective: To reveal the morphological and anatomical structure of the nasopalatine canal (NPC) and analyze its measurements via cone-beam computed tomography (CBCT). **Methods:** A total of 246 CBCT images were included in the study. NPC diameter, length, angle, distance from the IF to buccal bone (M1), distance from the NF to buccal bone (M2), and the distance from the middle of the NPC to buccal bone (M3) were measured. Statistical significance was assumed at $p < 0.05$. **Results:** There was a significant difference between gender and NPC length, M1 and M3 ($p = 0.008$, $p = 0.019$ and $p < 0.001$, respectively), and between the presence of teeth in the anterior maxilla and M1 ($p < 0.001$). There was a significant difference between the shape of NPC in the coronal plane and NPC angle ($p = 0.012$) and between the shape of NPC in the sagittal plane and NF diameter, IF diameter, M1 and the M3 ($p < 0.001$, $p = 0.006$, $p = 0.031$ and $p < 0.001$, respectively). **Conclusion:** NPC variations, gender, and the presence of teeth in the anterior maxilla could affect NPC measurements. Physicians planning surgery in the anterior maxilla should pay attention to this situation.

Key words: anatomy, cone-beam computed tomography, nasopalatine canal

How to cite this article: Tercanli H, Taş A, Ata GC. Cone-beam computed tomography assessment of morphologic and anatomic changes of the nasopalatine canal: Cross-sectional study. *J Dent Indones.* 2023;30(2): 128-135

INTRODUCTION

The anterior maxilla is an area that exposes a lot of surgical interventions, trauma, and loss of teeth,^{1,2} and the most prominent anatomical formation in this area is the nasopalatine canal (NPC). The NPC includes the nasopalatine nerve and the terminal branch of the nasopalatine artery, connective tissue, adipose tissue, and minor salivary glands. The nasopalatine nerve innervates the lower third of the nasal septum and the anterior portion of the hard palate.³

Dental aesthetics has become an important issue in dentistry, and patients have started to prefer implant treatment because of aesthetic concerns rather than function. Failure of implant therapy often leads to implant removal, followed by complex tissue and bone procedures.⁴ Implant contact with nervous tissue may cause the failure of osseointegration or sensory dysfunction.⁵ In the literature, difficulties and anatomical limitations related to the location of the NPC during the placement of implants in the maxillary central incisor region have been reported.^{6,7} For

avoiding the surgical complications needed radiological identification of anatomical structures is a necessity.⁸

This study aims to reveal the morphological and anatomical structure of the NPC and to analyze measurements of NPC by retrospective examination via cone-beam computed tomography (CBCT).

METHODS

This retrospective study was approved by the Ethics Committee of the Medical School of Akdeniz University and the study was carried out by the ethical rules of the Declaration of Helsinki (The ethics approval number was KAEK-474).

Data collection

The study material was selected from the archives of the Akdeniz University, Faculty of Dentistry, Department of Oral and Maxillofacial Radiology. The

The CBCT records of patients, who presented between February 2020 and January 2021 for different reasons, were assessed. The following exclusion criteria were used and a total of 246 CBCT image was included in the study: (1) CBCT images of the patients under the age of 18 years, (2) CBCT images of the patients with systemic disease affecting the bone structure, (3) CBCT images suggesting trauma, (4) CBCT images suggesting surgical history except for central incisors extraction, and (5) CBCT images with pathologies such as a cyst or any jaw diseases which were caused by developmental, metabolic or inflammatory factors in the anterior maxilla.

The CBCT images were divided into two groups according to the presence of teeth in the anterior maxilla: group 1: both maxillary central incisors present and group 2: one or two maxillary central incisors absent.

Images

The CBCT images were obtained with the Veraview X800 CBCT device (J. Morita Mfg. Corp., Kyoto, Tokyo) by the same X-ray technician by the manufacturer's instructions (320 μ m; 4.8 mA; 99 kVp and 17.9 sn for 15x 15x 51.2 field of view and 320 μ m; 4.8 mA; 99 kVp and 35.8 sn for 15x 15x 13.9 field of view). All the CBCT images were evaluated by the two investigators (with equal numbers), who was an expert in dental radiology, using the same LED monitor, approximately 40–50 cm away from the monitor. To maximize image quality, the images were evaluated in a dim light room and appropriate tonal adjustments. To avoid fatigue, only five CBCT images were evaluated per day by the investigators.

The investigators were calibrated by evaluating 20 CBCT images together, and the other images were evaluated separately by the investigators. CBCT images where observers were undecided were evaluated by a third investigator with eight years of experience in dental radiology and a final decision has been made. After four weeks, 50 randomly selected CBCT images were re-evaluated by the third observer and inter-observer agreement was assessed.

Evaluation of nasopalatine canal

In the axial plane; NPC shape is divided into four groups: round (with separation/ without separation), oval (with separation/ without separation), heart (with separation/ without separation), and others (teddy shaped, bean-shaped, flying balloon-shaped, triangle-shaped, etc.).⁹⁻¹¹ The number of Stenson's foramina (SF) was also evaluated as one SF, two SF, three SF, and more than three SF.¹¹

In the coronal plane; NPC shape is divided into three groups: Single channel, double channel, and Y-typed channel. The external border of NPC was also evaluated as V-shaped, Y-shaped, U-shaped, and reverse V-shaped.¹⁰

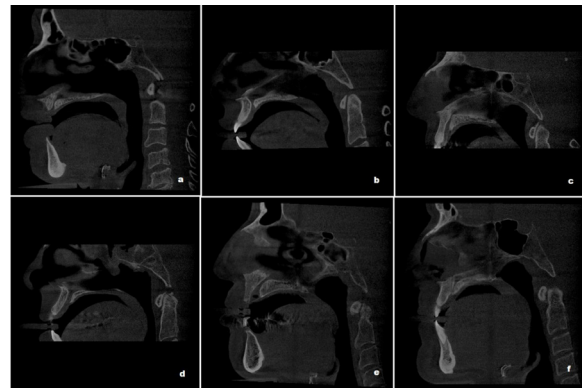


Figure 1. Nasopalatin canal shapes in the sagittal plane a: banana shaped; b: hourglass shaped; c: cone shaped; d: cylindrical; e: funnel shaped; f: tree branch.

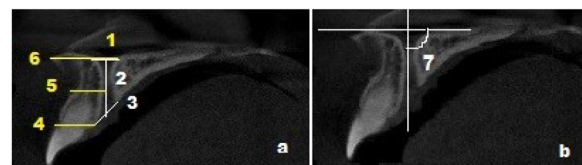


Figure 2. Measurements of the nasopalatine canal: a: 1: nasopalatine foramen diameter; 2: nasopalatine canal length; 3: incisive foramen diameter; 4: distance from the incisive foramen to the buccal bone plate; 5: the distance from the middle of the nasopalatine canal to the buccal bone wall; 6: distance from the nasopalatine foramen to the buccal bone plate; b: 7: nasopalatine canal angle.

In the sagittal plane; NPC shape is divided into six groups: hourglass, cone, funnel, banana, cylindrical, and tree branch⁸ (Figure 1). The direction course of NPC was also evaluated as vertical straight, vertical curved, slanted straight, and slanted curved.^{11,12}

In addition, the following measurements were made in the sagittal plane:

- nasopalatine foramen (NF) diameter,
- incisive foramen (IF) diameter,
- NPC length,
- NPC angle,
- distance from the buccal border of the IF to the facial aspect of the buccal bone plate (M1)
- distance from the buccal border of the NF to the facial aspect of the buccal bone plate (M2)
- the distance from the buccal border in the middle of the NPC to the facial aspect of the buccal bone wall (M3)¹¹ (Figure 2).

Statistical analysis

Data were statistically analyzed using an SPSS software package (version 23.0, SPSS Chicago, USA). The normality assumption was evaluated using the Kolmogorov–Smirnov method. The homogeneity of variance had been verified through Levene's test. For analysis of between two group differences, the independent samples t-test was applied for data with a normal distribution, and the Mann Whitney U test was used for data not displaying a normal distribution.

For analysis of more than two group differences, one-way ANOVA was applied for data with a normal distribution, and the Kruskal-Wallis test was used for data not displaying a normal distribution. When differences were found between the groups, the Tukey test was applied for data with a homogenous distribution, and the Games Howel test was used for data not displaying a homogenous distribution. Pearson chi-square test was used to analyze the difference between categorical variables. Statistical significance was assumed at $p < 0.05$. The inter-observer agreement was assessed by the Kappa coefficient for categorical variables and the interclass correlation coefficient (ICC) for numerical variables.

RESULTS

The CBCT images of 109 (44.3 %) male and 137 (55.7 %) female patients were included in the study; the age range was between 18 years and 78 years and the mean age of the patients was 43.5 ± 14.2 years.

There were 207 (84.1 %) patients in group 1 and 39 (15.9 %) patients in group 2. While there was no significant difference between gender and the presence of teeth in the anterior maxilla ($p = 0.138$), there was a significant difference between age and the presence of teeth in the anterior maxilla ($p < 0.001$).

The kappa coefficient was 0.89, 0.88, 0.87, 0.89, 0.86, and 0.88 for the shape of NPC in the axial plane, number of SF, the shape of NPC in the coronal plane, external border of NPC, the shape of NPC in sagittal plane and direction course of NPC, respectively. The ICC was 0.91, 0.99, 0.99, 0.97, 0.98, 0.95, and 0.97 for NF diameter, IF diameter, NPC length, M1, M2, M3, and NPC angle, respectively.

Morphologic and anatomic results of the nasopalatine canal

Table 1 shows the distribution of NPC shape, number of SF, external border of NPC, and direction course of NPC in axial, coronal, and sagittal planes. In the axial plane, the round shape consisted of 12 with separation; 128 without separation; the oval shape consisted of 14 with separation and 20 without separation; the heart shape consisted of 4 with separation and 15 without separation and others consisted of 14 teddies shaped, 14 bean-shaped, 9 flying balloon-shaped 8 triangles shaped, 3 spades shaped and 5 others shape. There was no significant difference between gender, age and presence of teeth in the anterior maxilla and NPC shape (in all planes), number of SF, external border of NPC, and direction course of NPC.

Table 1. Shape of the nasopalatine canal.

Plane	n (%)
Axial	
Shape of NPC	
Round	140 (56.9)
Others	53 (21.5)
Oval	34 (13.8)
Heart	19 (7.7)
Number of SF	
One	190 (77.2)
Two	36 (14.6)
Three	20 (8.1)
Coronal	
Shape of NPC	
Single channel	140 (56.9)
Y typed channel	78 (31.7)
Double-channel	28 (11.4)
External border of NPC	
U shaped	118 (48)
Reverse V-shaped	57 (23.2)
Y shaped	43 (17.5)
V-shaped	28 (11.4)
Sagittal	
Shape of NPC	
Hourglass-shaped	88 (35.8)
Cylindrical	61 (24.8)
Cone-shaped	42 (17.1)
Funnel-shaped	29 (11.8)
Banana-shaped	13 (5.3)
Tree branch	13 (5.3)
Direction course of NPC	
Slanted straight canal	130 (52.8)
Vertical straight canal	56 (22.8)
Slanted curved canal	36 (14.6)
Vertical curved canal	24 (9.8)

NPC: nasopalatin canal; SF: Stenson's foramina; n: number; % percent

Measurement results of the nasopalatine canal

The mean NF diameter was 3.56 ± 1.81 mm IF diameter was 7.99 ± 2.73 mm, NPC length was 14.24 ± 2.98 mm, M1, M2, and M3 was 6.24 ± 1.65 mm, 8.15 ± 1.81 mm and 6.96 ± 1.64 mm, respectively. In addition, the mean NPC angle was $110.55 \pm 11.38^\circ$. According to gender and the presence of teeth in the anterior maxilla the mean NF diameter, IF diameter, NPC length, NPC angle, M1, M2, and M3 were shown in Table 2. There was a significant difference between gender and NPC length, M1 and M3 ($p = 0.008$, $p = 0.019$, and $p < 0.001$, respectively). These measurements were greater in male patients. There was a significant difference between age and M1 ($p = 0.023$). In addition, there was a significant difference between the presence of teeth in the anterior maxilla and M1 ($p < 0.001$), and M1 was greater in group 1.

Table 2. Mean values of all measurements according to gender and presence of teeth in the anterior maxilla.

	NP diameter	IF diameter	NPC length	NPC angle	M1	M2	M3
Gender							
Male	3.71	7.84	14.80	109.94	6.50	8.41	7.4
Female	3.43	8.12	13.79	111.04	6.04	7.94	6.62
p	0.439	0.432	0.008*	0.377	0.019*	0.052	< 0.001*
Dental status							
Group 1	3.58	8.14	14.39	110.84	6.52	8.2	6.94
Group 2	3.49	7.22	13.47	109.02	4.77	7.9	7.07
p	0.873	0.064	0.107	0.344	< 0.001*	0.39	0.683

NF: nasopalatine foramen; IF: incisive foramen; NPC: nasopalatine canal; M1: distance from the buccal border of the IF to the facial aspect of the buccal bone plate; M2: distance from the buccal border of the NF to the facial aspect of the buccal bone plate; M3: the distance from the buccal border in the middle of the NPC to the facial aspect of the buccal bone wall; group 1: both maxillary central incisors present; group 2: one or two maxillary central incisors absent; *: < 0.05.

Table 3. External border of NPC responsible for differences.

Parameter	V-shaped	Y shaped	U shaped	Reverse V shaped
NP diameter				
V-shaped	NS	NS	0.004
Y shaped	NS	NS	0.034
U shaped	NS	NS	< 0.001
Reverse V shaped	0.004	0.034	< 0.001
IF diameter				
V-shaped	0.011	NS	0.045
Y shaped	0.011	NS	NS
U shaped	NS	NS	NS
Reverse V-shaped	0.045	NS	NS
NPC length				
V-shaped	0.004	NS	NS
Y shaped	0.004	0.002	0.035
U shaped	NS	0.002	NS
Reverse V-shaped	NS	NS	0.035
NPC angle				
V-shaped	0.005	0.037	0.002
Y shaped	0.005	NS	NS
U shaped	0.037	NS	NS
Reverse V-shaped	0.002	NS	NS

NF: nasopalatine foramen; IF: incisive foramen; NPC: nasopalatin canal; NS: non significant

Measurement results according to nasopalatine canal morphology and anatomy

Axial plane

There were no significant differences between the shape of NPC in the axial plane and NF diameter, IF diameter, NPC length, NPC angle, M1, M2, and M3 (p = 0.079, p = 0.137, p = 0.158, p = 0.236, p = 0.714, p = 0.401 and p = 0.078, respectively). There was a significant difference between the number of SF in the axial plane and NPC length, and NPC angle (p = 0.038 and p = 0.018, respectively). This difference was caused by the difference between one SF and two SF in both parameters (p = 0.034 for NPC length and p = 0.018 for NPC angle).

Coronal plane

There was a significant difference between the shape of NPC in the coronal plane and NF diameter (p =

0.012), and this difference is due to the difference between single channel and double channel (p = 0.020), and single channel and Y typed channel (p = 0.017). There was no significant difference between the other measurements and the shape of the NPC in the coronal plane.

There was a significant difference between the external border of NPC in the coronal plane and NF diameter, IF diameter, NPC length, and NPC angle (p < 0.001, p = 0.004, p = 0.001, and p = 0.002, respectively). Table 3 shows the external border of NPC responsible for differences.

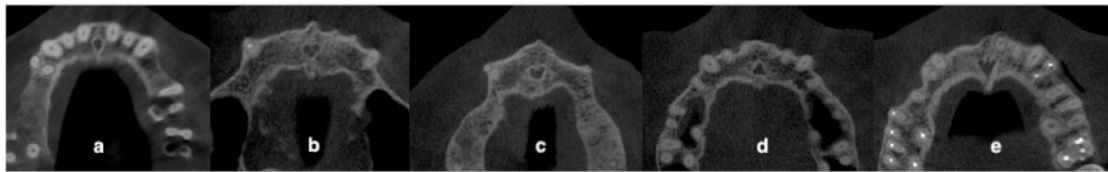


Figure 3. Other nasopalatine canal shapes in the axial plane: a: flying balloon-shaped; b: teddy shaped; c: bean-shaped; d: triangle-shaped; e: spades shaped.

Sagittal plane

There was a significant difference between the shape of NPC in the sagittal plane and NF diameter, IF diameter, M1, and the M3 ($p < 0.001$, $p = 0.006$, $p = 0.031$, and $p < 0.001$, respectively). While this difference is due to the difference between hourglass and cone ($p \leq 0.001$), hourglass and funnel ($p \leq 0.001$), and hourglass and tree branch ($p = .04$) in NF diameter, it is due to the difference between funnel and banana ($p = 0.019$), funnel and cylindrical ($p < 0.033$) in IF diameter. In addition, this difference is due to the difference between banana and hourglass ($p < 0.001$), banana and cylindrical ($p = 0.001$), and banana and tree branches ($p = 0.002$) in M3. There was no significant difference in pairwise comparisons in M1.

There was a significant difference between the direction course of NPC in the sagittal plane and NF diameter, NPC length, NPC angle, and M1 ($p = 0.001$, $p < 0.001$, $p = 0.047$, and $p < 0.001$, respectively). While this difference is due to the difference between vertical straight and slanted straight ($p = 0.006$) and vertical straight and slanted curved ($p = 0.002$) in NF diameter, it is due to the difference between vertical straight and vertical curved ($p = 0.026$) and vertical straight and slanted curved ($p < 0.001$) in NF length. In addition, this difference is due to the difference between vertical straight and slanted straight ($p = 0.001$) and vertical curved and slanted straight ($p = .038$) in NPC angle. There was no significant difference in pairwise comparisons in M1.

DISCUSSION

Neurosensory disturbances and hemorrhage are the most common complications related to implant placement surgeries. Jacobs et al. reported the increasing rate of surgical inventions and underlined the potential risks and anatomic variations in that area.³ Kraut and Boyden reported that NPC measurements impeded implant placement in approximately 4 % of cases about maxillary central incisor implants.⁶ For that reason, it is important to evaluate the position, morphology, and dimensions of the nasopalatine canal to increase the success of surgical procedures, establish theories that can explain the etiopathogenesis of lesions in this anatomical region, and prevent possible complications in this region.^{12,13}

A detailed radiographic assessment must be done before dental implant surgery to determine the accurate location and dimensions of the anatomic structures.⁷ Although conventional imaging methods have low radiation doses, because of two-dimensional evaluations of anatomic structures they are not considered safe before the surgical procedure.¹⁴ CBCT has been recently accepted as the most ideal imaging method for the dentomaxillofacial region due to its low radiation dose in comparison with computed tomography and its cheaper cost.¹⁴ CBCT was used in this study because it gives more valuable information than conventional two-dimensional radiographic methods. Although many studies have been conducted on NPC morphology and anatomy, to the best of the authors' knowledge, the current study can be the most comprehensive.

Different imaging techniques can be used for NPC evaluation.^{2,3,7,11,12} Gönül et al classified NPC in all three anatomical planes and used multidetector computed tomography as an imaging technique.¹¹ In the current study, NPC evaluation was performed in all three planes, and CBCT, which is accepted as a more accurate, valuable imaging technique by many dentomaxillofacial authorities,¹⁵ was used as the imaging technique.

Morphology and anatomy of the nasopalatine canal

In the current study, round shapes NPC was the most NPC shape in the axial plane ($n = 140$, 56.9%; 12 of these with separation and 28 of these without separation). While this result is greater than Acar and Kamburoğlu ($n = 110$, 44%; 20 of these with separation and 90 of these without separation)⁹ and Gönül et al (50%),¹¹ this result is lower than Bahşi et al ($n = 113$, 75.3% in level of nasopalatine foramen and $n = 94$, 62.7% in incisive foramen).¹⁰ While Bahşi et al found a significant relationship between gender and NPC shape (in nasopalatine foramen),¹⁰ Acar and Kamburoğlu didn't find such a relationship,⁹ similar to the current study. On the other hand, Gönül et al did not include this result in their study. Gönül et al added teddy-shaped, bean-shaped, and flying balloon-shaped to NPC shape classification in the axial section, and these shapes were seen in one, one, and two patients, respectively.¹¹ In the current study authors determined another variation which a shape similar to spades in

three patients. In addition, the current study showed teddy-shaped, bean-shaped, and flying balloon-shaped in 14, 14, and 9 patients, respectively (Figure 3). The fact that different variations were observed in the axial plane in both studies makes the authors think that a new shape classification can be made in this plane and therefore more studies should be conducted.

NPC bifurcates towards to nasal septum and nasal cavity floor⁶ and all the foramen here are called SF.¹⁷ The NPC may be divided into any number of canaliculi via the bony septum.¹² While Sicher reported SF might be present in up to six separate foramina,¹⁸ Song et al. showed there can be up to four channels at the middle level of NPC.¹² While one SF is seen the most in some studies,^{2,8,10,12} other studies show two SF was the most.¹¹ In addition four SF is seen between 2% and 8.9%.^{8,11,12} In the current study, one SF (77.2%) was detected the most, and this incidence was higher than the results of other researchers (42.9% for Song et al,¹² 44% for Liang et al,² 44.3% for Etoz and Sisman.⁸ There was no more than three SF detected in the current study.

It was stated that while less than 50% of the sample size was a single channel in some of the studies^{1,10,12,19} examining the shape of the NPC in the coronal plane, more than 50% of the single-channel was observed in other studies.^{8,11,20} The current study showed the most shape of the NPC in the coronal plane was single channel (56.9%) and followed by Y typed channel (31.7%) and double channel (11.4%). Etöz and Sisman and Bahşi et al. didn't find a significant difference between gender and NPC shape (in the coronal plane),¹⁰ similar to the current study. In addition, the current study showed that most external border of NPC was U-shaped (48%). Bahşi et al. found that most external border of NPC as V-shaped (44%).¹⁰

The most seen NPC shape in the sagittal plane was found differently by the researchers. While Mardinger et al,⁷ Liang et al,² Fernandez Alonzo et al,¹⁹ Gönül et al,¹¹ and Bahşi et al¹⁰ found the most seen NPC shape in the sagittal plane as cylindrical (50.7%, 53.4%, 48.2%, 48%, and 28.7%, respectively), Etoz and Sisman found the most seen NPC shape in the sagittal plane as hourglass (38.8%)⁸ and Hakbilen and Magat found as conical (26.17%).²¹ The current study results showed similar results with Etoz and Sisman and the most seen NPC shape in the sagittal plane was hourglass (35.8%).⁸ This is followed by cylindrical (24.8%), cone (17.1%), and funnel (11.8%). Tree branches and bananas were equally common (5.3%) and these shapes were the least seen NPC shape in the sagittal plane for the current study. This result is similar to other research.^{7,8,19,21} In the current study, there was no significant difference between NPC shape in the sagittal plane and gender similar to other studies.^{8,10,21} While the most seen direction course of NPC was vertical curved (40%) according to Gönül et al,¹¹ it was slanted straight (53%) in the current study and followed by vertical straight

(22.8%), slanted curved (14.6%) and vertical curved (9.9%).

Özçakır-Tomruk et al found no relationship between NPC shape and dental status in a coronal plane similar to the current study.²⁰ On the other hand, Hakbilen and Magat found a significant relationship which contradicted the current study in the sagittal plane.²¹

The different results obtained in the referenced studies may be due to the different inclusion criteria in the studies, the different sample sizes, and the evaluation of the images at different levels in all three planes. In the presented study, when determining the shape of the NPC, the external border of NPC, the number of SF, and the direction course of NPC, the part where it appears most clearly in the CBCT planes was taken into account.

Measurement of the nasopalatine canal

The sagittal plane is the most widely studied plane for surgical planning and for that reason it was used for evaluating NPC measurements in the current study.¹⁹ According to Mardinger et al. NPC tends to enhance.⁷ Among the referenced studies, mean NF diameter has been reported between 2.76 mm and 4.13 mm, mean IF diameter reported between 3.17 mm and 6.47 mm, and mean NPC length reported between 10.34 mm and 13.65 mm.^{1,8,10,20-22} In the current study, the mean NF diameter was found to be 3.56 ± 1.81 mm compatible with the referenced studies, while the mean IF diameter and mean NPC length was found to be slightly higher than the referenced studies (7.99 ± 2.73 mm and 14.24 ± 2.98 mm, respectively). In the present study, increasing values were found in the measurements from the crest to the apical, consistent with the referenced studies.^{1,21,22}

When the relationship between NPC measurements and gender was examined, it was seen that the measurements that are significant in the referenced studies are higher in males than in females, such as in the current study.^{1,8-11,21,22} This can be explained by the fact that adult male bones are larger and stronger than female bones.²³ On the other hand, Friedrich et al determined that the diameter of the NPC showed no dependency on gender.²⁴

Mardinger et al reported that the buccal plate widths decreased in older patients.⁷ This may be explained by bone remodeling and increased structural loss in older patients.²¹ Among all measurements, there was only a significant difference between M1 and age in the current study. This result similar with Acar and Kamburoğlu, Gönül et al, Hakbilen and Magat, and Khojastepour et al.^{9,11,21,22} Other referenced studies didn't show such a result in M1. On the other hand Acar and Kamburoğlu, and Hakbilen and Magat showed a significant difference between M3 and age in their study.^{9,21} Such differences in gender and ages may be caused by sample size in different studies.

Maxillary central incisor status affects measurements because tooth extraction causes bone resorption and remodeling of anatomical structures.^{2,7} According to Acar and Kamburoğlu, only NP diameter was unaffected by maxillary incisor status.⁹ While Etoz and Sisman and Özçakır Tomruk et al found a significant difference according to the state of edentulism in NPC length ($p < 0.001$),^{8,20} they didn't find a significant difference in IF diameter. Hakbilen and Magat found a significant difference in NPC length, M1, and M3 measurements ($p < 0.001$ for all).²¹ In the current study, almost all measurements were reduced in group 2. However, this decrease was significant only in M1 ($p < 0.001$) similar to Gönül et al ($p < 0.001$).¹¹ Song et al showed that incisive foramen was located slightly more anteriorly in edentulous cases than in dentulous cases.¹² Considering this situation, the results of the current study are not surprising. The reason for the differences between studies may be the different classifications of dental status in each study. In the present study, due to the low number of the absence of maxillary incisors, the absence of one incisor and the absence of two incisors were presented as a single group.

Measurement results according to nasopalatine canal morphology and anatomy

Among the referenced studies, there is a small number of studies examining the difference between NPC shape and NPC measurements in coronal and sagittal planes.^{21,22} However, to the best of the author's knowledge, there was no such study examining the difference between the NPC shapes in the axial plane, number of SF, external border of NPC in the coronal plane, and direction course of NPC in the sagittal plane and NPC measurements. Therefore, it is thought that these results in the current study may guide further studies.

While the current study showed no significant differences between the shape of NPC in the axial plane and measurements. There was a significant difference between the number of SF in the axial plane and NPC length, NPC angle ($p = 0.038$ and $p = 0.018$, respectively), and this difference was caused by the difference between one opening SF and two openings SF in both parameters.

In the coronal plane, Khojastepour et al found a significant difference between NPC shapes and NP diameter ($p = 0.006$),²² similar to the current study. On the other hand, in the aforementioned article, it is not specified which NPC shape the difference originates from. There was a significant difference between the external border of NPC and NF diameter, IF diameter, NPC length, and NPC angle ($p < 0.001$, $p = 0.004$, $p = 0.001$, and $p = 0.002$, respectively) in the current study. This difference was caused by the difference between reverse V-shaped and other shapes in NP diameter, between V-shaped and Y shaped and reverse V-shaped in IF diameter, between Y shaped and other shapes in

NPC length, and between V-shaped and other shapes in NPC angle.

In the sagittal plane, Hakbilen and Magat found a significant difference in mean values of NPC all measurements ($p < 0.001$) according to NPC shapes.²¹ In addition, while Bahşi et al. found a statistically significant relationship between the shape of the NPC and NF diameter ($p = 0.005$),¹⁰ they did not give any information about which group caused this difference, they only emphasized that the largest NF diameter was in the hourglass-shape. There was a significant difference between the shape of NPC in the sagittal plane and NF diameter, IF diameter, M1, and the M3 ($p < 0.001$, $p = 0.006$, $p = 0.031$ and $p < 0.001$, respectively) at the current study, and this difference was caused by the difference between funnel-shaped and hourglass-shaped ($p < 0.001$), between cone-shaped and cylindrical ($p = 0.016$) and hourglass-shaped ($p < 0.001$) and between a tree branch and hourglass-shaped ($p = 0.047$) in NF diameter.

This study has some limitations. The authors consider that the most important limitation is the failure to calculate the sample size. On the other hand, all CBCT images that met the inclusion criteria were included in the study. In addition, the fact that the parameters were not distributed symmetrically may have affected the results of the study. However, in order to prevent this situation, non-parametric tests were used for the analysis of parameters that are not normally distributed in the present study.

CONCLUSION

It is necessary to pay attention to the variations and measurements of NPC during implant placement or other surgical in the anterior maxilla where the aesthetic concern is at the forefront and to evaluate the relevant region in three dimensions. It was seen that NPC variations, gender, and presence of teeth in the anterior maxilla could affect NPC measurements.

CONFLICT OF INTEREST

The authors declare that there is no conflict of interest.

FUNDING

No financial support was received.

REFERENCES

1. Bornstein MM, Balsiger R, Sendi P, von Arx T. Morphology of the nasopalatine canal and dental implant surgery: A radiographic analysis of 100

- consecutive patients using limited cone-beam computed tomography. *Clin Oral Implants Res.* 2011; 22(3):295-301.
2. Liang X, Jacobs R, Martens W, Hu Y, Adriaensens P, Quirynen M, Lambrichts I. Macro- and micro-anatomical, histological and computed tomography scan characterization of the nasopalatine canal. *J Clin Periodontol.* 2009; 36(7):598-603.
 3. Jacobs R, Lambrichts I, Liang X, Martens W, Mraiwa N, Adriaensens P, Gelan J. Neurovascularization of the anterior jaw bones revisited using high-resolution magnetic resonance imaging. *Oral Surg Oral Med Oral Pathol Oral Radiol Endod.* 2007; 103(5):683-93.
 4. Buser D, Martin W, Belser UC. Optimizing esthetics for implant restorations in the anterior maxilla: anatomic and surgical considerations. *Int J Oral Maxillofac Implants.* 2004; 19 Suppl:43-61.
 5. Mraiwa N, Jacobs R, Van Cleynenbreugel J, Sanderink G, Schutyser F, Suetens P, van Steenberghe D, Quirynen M. The nasopalatine canal revisited using 2D and 3D CT imaging. *Dentomaxillofac Radiol.* 2004; 33(6):396-402.
 6. Kraut RA, Boyden DK. Location of incisive canal in relation to central incisor implants. *Implant Dent.* 1998; 7(3):221-5.
 7. Mardinger O, Namani-Sadan N, Chaushu G, Schwartz-Arad D. Morphologic changes of the nasopalatine canal related to dental implantation: A radiologic study in different degrees of absorbed maxillae. *J Periodontol.* 2008; 79(9):1659-62.
 8. Etoz M, Sisman Y. Evaluation of the nasopalatine canal and variations with cone-beam computed tomography. *Surg Radiol Anat.* 2014; 36(8):805-12.
 9. Acar B, Kamburoğlu K. Morphological and volumetric evaluation of the nasopalatine canal in a Turkish population using cone-beam computed tomography. *Surg Radiol Anat.* 2015; 37(3):259-65.
 10. Bahşi I, Orhan M, Kervancıoğlu P, Yalçın ED, Aktan AM. Anatomical evaluation of nasopalatine canal on cone beam computed tomography images. *Folia Morphol (Warsz).* 2019; 78(1):153-62.
 11. Gönül Y, Bucak A, Atalay Y, Beker-Acay M, Çalışkan A, Sakarya G, Soysal N, Cimbar M, Özbek M. MDCT evaluation of nasopalatine canal morphometry and variations: An analysis of 100 patients. *Diagn Interv Imaging.* 2016; 97(11):1165-72.
 12. Song WC, Jo DI, Lee JY, Kim JN, Hur MS, Hu KS, Kim HJ, Shin C, Koh KS. Microanatomy of the incisive canal using three-dimensional reconstruction of microCT images: An ex vivo study. *Oral Surg Oral Med Oral Pathol Oral Radiol Endod.* 2009; 108(4):583-90.
 13. Jacob S, Zelano B, Gungor A, Abbott D, Naclerio R, McClintock MK. Location and gross morphology of the nasopalatine duct in human adults. *Arch Otolaryngol Head Neck Surg.* 2000; 126(6):741-8.
 14. Harris D, Buser D, Dula K, Grondahl K, Haris D, Jacobs R, Lekholm U, Nakielny R, van Steenberghe D, van der Stelt P; European Association for Osseointegration. E.A.O. guidelines for the use of diagnostic imaging in implant dentistry. A consensus workshop organized by the European Association for Osseointegration in Trinity College Dublin. *Clin Oral Implants Res.* 2002; 13(5):566-70.
 15. Teughels W, Merheb J, Quirynen M. Critical horizontal dimensions of interproximal and buccal bone around implants for optimal aesthetic outcomes: A systematic review. *Clin Oral Implants Res.* 2009; 20 Suppl 4:134-45.
 16. Abrams AM, Howell FV, Bullock WK. Nasopalatine cysts. *Oral Surg Oral Med Oral Pathol.* 1963; 16:306-32.
 17. Neves FS, Oliveira LK, Ramos Mariz AC, Crusoé-Rebello I, de Oliveira-Santos C. Rare anatomical variation related to the nasopalatine canal. *Surg Radiol Anat.* 2013; 35(9):853-5.
 18. Sicher H. Anatomy and oral pathology. *Oral Surg Oral Med Oral Pathol.* 1962; 15:1264-9.
 19. Fernández-Alonso A, Suárez-Quintanilla JA, Muínelo-Lorenzo J, Bornstein MM, Blanco-Carrión A, Suárez-Cunqueiro MM. Three-dimensional study of nasopalatine canal morphology: A descriptive retrospective analysis using cone-beam computed tomography. *Surg Radiol Anat.* 2014; 36(9):895-905.
 20. Özçakır-Tomruk C, Dölekoğlu S, Özkurt-Kayahan Z, İlgüy D. Evaluation of morphology of the nasopalatine canal using cone-beam computed tomography in a subgroup of Turkish adult population. *Surg Radiol Anat.* 2016; 38(1):65-70.
 21. Hakkıbil S, Magat G. Evaluation of anatomical and morphological characteristics of the nasopalatine canal in a Turkish population by cone beam computed tomography. *Folia Morphol (Warsz).* 2018; 77(3):527-35.
 22. Khojastepour L, Haghnegahdar A, Keshtkar M. Morphology and dimensions of nasopalatine canal: A radiographic analysis using cone beam computed tomography. *J Dent (Shiraz).* 2017; 18(4):244-50.
 23. Celbis O, Iscan MY, Soysal Z, Cagdir S. Sexual diagnosis of the glabellar region. *Leg Med (Tokyo).* 2001; 3(3):162-70.
 24. Friedrich RE, Laumann F, Zrnc T, Assaf AT. The nasopalatine canal in adults on cone beam computed tomograms-A clinical study and review of the literature. *In Vivo.* 2015; 29(4):467-86.

(Received February 2, 2023; Accepted August 7, 2023)