

8-31-2021

Comparison of Shaping Ability between Continuous Rotary and Manual Instrumentations in Pediatric Endodontics

Burcu Güçyetmez Topal

Department of Pedodontics, Afyonkarahisar Health Sciences University, Faculty of Dentistry, Afyonkarahisar, Turkey., dt.burcugucyetmez@hotmail.com

Seda Falakaloğlu

Department of Endodontics, Afyonkarahisar Health Sciences University, Faculty of Dentistry, Afyonkarahisar, Turkey, sedafalakaloglu@gmail.com

Hatice Türkoğlu

Department of Pedodontics, Afyonkarahisar Health Sciences University, haticeturkoglu95@gmail.com

Follow this and additional works at: <https://scholarhub.ui.ac.id/jdi>



Part of the [Dental Materials Commons](#), [Endodontics and Endodontology Commons](#), and the [Pediatric Dentistry and Pedodontics Commons](#)

Recommended Citation

Güçyetmez Topal, B., Falakaloğlu, S., & Türkoğlu, H. Comparison of Shaping Ability between Continuous Rotary and Manual Instrumentations in Pediatric Endodontics. *J Dent Indones.* 2021;28(2): 70-75

This Article is brought to you for free and open access by the Faculty of Dentistry at UI Scholars Hub. It has been accepted for inclusion in Journal of Dentistry Indonesia by an authorized editor of UI Scholars Hub.

Comparison of Shaping Ability between Continuous Rotary and Manual Instrumentations in Pediatric Endodontics

Cover Page Footnote

ACKNOWLEDGMENT The authors thank İnci Dental for providing endodontic instruments. CONFLICT OF INTERESTS No potential conflict of interest relevant to this article was reported.

ORIGINAL ARTICLE

Comparison of Shaping Ability between Continuous Rotary and Manual Instrumentations in Pediatric Endodontics

Burcu Güçyetmez Topal¹, Seda Falakaloğlu^{*2}, Hatice Türkoğlu¹

¹*Department of Pedodontics, Afyonkarahisar Health Sciences University, Faculty of Dentistry, Afyonkarahisar, Turkey.*

²*Department of Endodontics, Afyonkarahisar Health Sciences University, Faculty of Dentistry, Afyonkarahisar, Turkey*

**Correspondence e-mail to: sedafalakaloglu@gmail.com*

ABSTRACT

Objective: The aim of this in vitro study was to evaluate the efficacy of rotary EndoArt Ni-Ti Gold Pedo Kit and K-files in shaping ability, canal transportation, centering ability and instrumentation time in primary molars. **Methods:** For the study total of 30 extracted primary molars root with minimum 7mm root length were selected. Shaping of root canals in primary molars were done using the two systems, and CBCT and specialized software were used for scanning and analysis of pre-operative and post-operative to evaluate the groups for their shaping properties, apical transportation and preparation time in primary root canals. **Results:** No differences were found in canal transportation measures and instrumentation time between the two groups ($p>0.05$). The EndoArt group removed more dentin compared to K-file in all sides of the root curvature. The statistical differences were significant for coronal and middle third of the root ($p<0.05$). **Conclusions:** Under the conditions of this study, rotary EndoArt Ni-Ti Gold Pedo Kit provided more conical canals than K-files in primary teeth.

Key words: CBCT, EndoArt Pedo, Hand K-files, primary teeth

How to cite this article: Topal BG, Falakaloğlu S, Türkoğlu H. Comparison of shaping ability between continuous rotary and manual instrumentations in pediatric endodontics. *J Dent Indones.* 2021;28(2):70-75.

INTRODUCTION

One of the most important objective in pediatric dentistry is to keep the tooth present in the dental arch until its physiological exfoliation. Early extraction of primary teeth leads to space loss, functional, aesthetical and psychological problems so, pulpectomy of primary teeth with irreversible pulpitis or necrosis should be considered as a treatment of choice.¹ The success of endodontic treatments depends on cleaning of debris, shaping the root canals for providing a path for irrigants and suitable obturation materials, retaining the unity of radicular anatomy.² However, anatomic complexities of primary teeth such as accessory canals, anastomoses, thin and curved roots, close proximity to the succedaneous tooth germ and alterable resorbed root apex preclude the possibility of complete removal of all radicular pulp and can lead to undesirable complications. Additionally, difficulties in behavioural management of child patients making pediatric endodontics more challenging and increase the importance of time spent on treatment.^{3,4}

The hand files are commonly used for pulpectomy in primary teeth but manual preparation techniques have some limitations regarding time consumption and iatrogenic errors.^{5,6} Due to limitations of hand files, rotary systems were introduced to pediatric endodontics.⁷ Rotary systems for pulpectomy of primary teeth was affordable, fast, provide uniform shaping and filling and preserve the original anatomy of root canals.⁶ However in a systematic review, it was found that the clinical and radiographic success rates of rotary systems and manual instrumentation were equivalent in primary teeth.⁸ Also, it is reported that this systems leave unclear areas due to centred in root canals throughout rotation.⁹ The vast majority of rotary systems are designed according to permanent tooth anatomy, therefore it is difficult to use for pediatric patients with limited mouth opening and it causes challenges in shaping root canals of primary tooth. So, special pediatric rotary file systems with modified taper, length, and tip size have been developed.^{10,11}

One of the new developed pediatric rotary system is EndoArt Ni-Ti Gold Pedo Kit (Incidental, Istanbul, Turkey) which was designed with modified length and taper introduced for pulpectomy of primary teeth. EndoArt Ni-Ti Gold Pedo Kit heat-treated NiTi rotary instrument system is made of a controlled memory wire. According to the manufacturer, this system has convex triangle cross-section design. This system contains three NiTi rotary files with a total length of 18mm.¹²

There are no studies in the accessible literature evaluating the newly released EndoArt Ni-Ti Pedo Kit rotary file system. The aim of the present study was to compare the shaping ability and instrumentation time between stainless steel K-files and EndoArt Ni-Ti Gold rotary system in primary teeth.

METHODS

Ethics committee permissions were approved by the Local Ethics Committee (No: 2011-KAEK-2-2020/8). A total of 30 human primary molar teeth (15 maxillary, 15 mandibular) extracted either due to orthodontic treatment or those that have been over retained beyond the age of exfoliation. Teeth which have undergone pulpectomy, teeth with internal or extensive pathological root resorption were excluded from the study. Primary mandibular molar distal roots and maxillary molar palatal roots were preferred due to their generally large, curved, single canal. The roots were separated for standardization with root length of 7 mm for the study.¹³ The teeth selected for the inclusion into the study were stored in sterile water until the experimental time.

The #15 K-file (VDW GmbH, Munich, Germany) was advanced within the canal until the tip was seen through the major apical foramen and the working length was determined 1 mm shorter than this length. Roots were randomly distributed to one of two groups of 15 roots (8 distal roots of the mandibular teeth, 7 palatal roots of the maxillary teeth) each. All instrumentation procedures were performed by single operator. Each instrument was used in four canals, simulating a molar with four canals. A total of 10ml 2.5% NaOCl and 10ml distilled water were used for irrigation with a 30-G NaviTip needle (Ultradent Products Inc., South Jordan, UT, USA) between the use of each instrument in both groups.

The roots were mounted on a custom-made holder in which silicone boxes could be placed in the same position before and after instrumentation. For standardization, the roots were scanned at 13 mA, 90 kVp, 12 seconds and 6×8cm field of view with cone beam computed tomography (CBCT, GXDP-700, Gendex Dental Systems, Hatfield, USA).

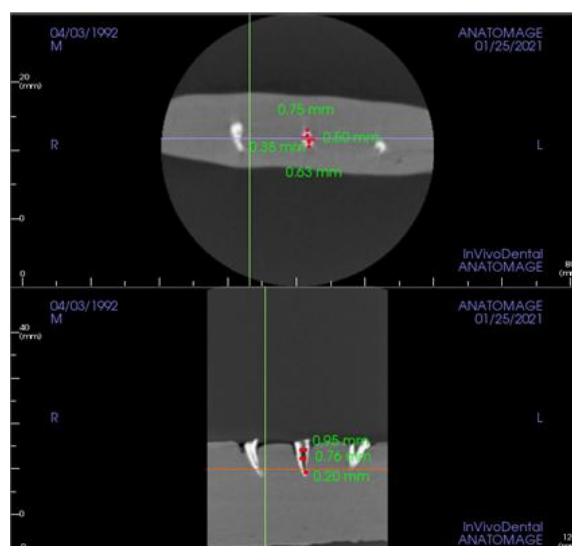


Figure 1. CBCT image showing measurements of root canal taper at the cervical, middle and apical third of the root and apical transportation

Group I (K file): Mechanical preparation was performed by hand in a step-back manner using K-files (VDW GmbH, Munich, Germany) up to size 25 at the apical foremen.

Group II (EndoArt Ni-Ti Gold Pedo Kit): Canal preparation was used with EndoArt Ni-Ti Gold Pedo Kit rotary instruments. The adopted file sequence was 15/06, 20/04, 25/04 at 300rpm with a low torque setting (1.5 N.cm) to the full length of the canal with endomotor. (VDW Gold, VDW, Munich, Germany).

Invivo5 Anatomy Imaging Software (Anatomage, USA) was used for the measurements of root canal taper at the cervical, middle and apical third of the root.¹³ The transportation was measured at 1 mm levels from the apical end of the root before and after instrumentation (Figure 1). Mesiodistal transportation, buccolingual transportation were calculated with these formulas.

Canal transportation was determined using the following formulas:^{14,15}

The distance of mesiodistal transportation: (a1-a2) - (b1-b2)

The distance of buccolingual transportation: (c1-c2) - (d1-d2)

The related edges of the uninstrumented canal were coded as a1 (mesial), b1 (distal), c1 (buccal), and d1 (lingual); the related edges of the instrumented canal were coded as a2 (mesial), b2 (distal), c2 (buccal), and d2 (lingual) which were the shortest distances from edges of the root.

According to these formulas, 0 means no canal transportation¹⁴, whereas positive and negative values show mesial and buccal and distal or lingual transportation.¹⁵

Table 1. Statistical comparisons of mean canal transportation and centering ratio in apical third and instrumentation time (mean and standard deviation) of K-files and EndoArt rotary files

	K-File Mean(SD)	EndoArt Mean (SD)	p-value
Mean canal transportation in apical third			
Bucco-lingual	0.011 (0.087)	-0.002 (0.128)	0.755
Mesio-distal	0.027 (0.112)	-0.044 (0.092)	0.070
Mean instrumentation time (min)			
	4.430 (1.112)	4.868 (1.157)	0.299

SD: Standard deviation
* Statistically significant values (p<0.05)

Measurement of instrumentation time

A digital chronometer was used for the measurement of instrumentation time. The time of active instrumentation, instrument changes within the sequence protocol and irrigation were include to the total instrumentation time.

Statistical analysis

The statistical analysis of the data were done with IBM. SPSS statistics software package program (SPSS Inc., Chicago, Illinois, USA, Version 23.0). The Levene and Shapiro-Wilk tests were used for the determination of the homogeneity of variance and normality. To find the significant difference between the groups, the unpaired t-test was used. For descriptive statistics, mean and standard deviation were used. Statistical significance was set at p<0.05.

RESULTS

The sample comprised 30 root canals of primary teeth (15 in each group). The canal transportation in the apical third results were shown in Table 1. No differences between the two groups were found (p>0.05).

The mean instrumentation time observed for instrumentation with rotary EndoArt files is 4.868 min with a standard deviation of 1.157. The mean instrumentation time observed for instrumentation with K-file is 4.430 min with a standard deviation of 1.112. The mean instrumentation time between the two groups were not statistically significant (p>0.05). Table 2 shows the mean dentin removal after instrumentation. The EndoArt rotary file provided more conical canal taper compared with the K-file.

Table 2. Statistical comparisons of mean (standard deviation) dentin removal after instrumentation in cervical, middle and apical third of the root between K-files and EndoArt rotary files

Mean dentin removal	Mean (SD)	p-value
Coronal Third		
K-File	0.167 (0.092)	0.013*
EndoArt	0.269 (0.118)	
Middle Third		
K-File	0.076 (0.067)	0.004*
EndoArt	0.145 (0.053)	
Apical Third		
K-File	0.088 (0.078)	0.071
EndoArt	0.133 (0.049)	

SD: Standard deviation
* Statistically significant values (p<0.05)

The EndoArt group removed more dentin compared to K-file in all sides of the root curvature. The statistical differences were significant for coronal and middle third of the root (p<0.05).

DISCUSSION

It is crucial to evaluate the effect of different instruments on root canal geometry in different roots for endodontic treatment in primary teeth. Therefore, the objective of this study was to evaluate pulpectomy of primary molar root canals with K type hand-files and EndoArt rotary files using CBCT analysis.

In accordance with the anatomical structure of the primary tooth and pediatric patients cooperation, special file systems for primary teeth are released to overcome the disadvantage of the existing rotary files, one of which was EndoArt Ni-Ti Pedo Kit. It has convex triangle cross-section design and consists of three NiTi rotary files with a total length of 18mm. In the accessible literature, no study has evaluated the comparison of shaping ability of EndoArt Ni-Ti Gold Pedo Kit and K-files. So, in this study canal transportation, centric ratio, mean dentin removal and instrumentation time were evaluated.

Various methods such as histological examination, serial sectioning, scanning electron microscope, radiographic comparisons, silicon modeling of instrumented teeth, microcomputer tomography have been used to evaluate the shaping capabilities of root canal file systems. In addition, CBCT is one of the methods used today to evaluate the shaping capabilities in examinations which ensured elaborate three-dimensional observation.¹³ The most important advantage of this method is

that the tooth does not need to be cut before and after the procedure.^{16,17} Additionally, CBCT provides images in both orthogonal and oblique planes so it is advantageous in terms of measuring centering ratio, apical transportation and dentin thickness.¹⁸

In the present study, extracted primary molars used because of natural dentin provide more reliability of results compared with artificial resin canals. In addition, for simulating clinical situations minimum 7mm of root length were selected where at least two-thirds of root length is considered to be necessary. Canal transportation is the iatrogenic change in the physiological pathway of the root canal and it occurs mainly because of the rigidity of endodontic files.¹⁵ Physiological or pathological resorption in the apical and furcation areas, anastomoses, secondary canals and various anatomical variations of primary teeth increase the importance of canal transportation.¹⁹ So, minimal canal transportation is required during endodontic treatment of primary teeth. The occurrence of up to 0.15mm of canal transportation has been considered to be acceptable.²⁰ In this study, there was no significant difference between the apical transportation values of EndoArt rotary and K files and value of canal transportation were seen in apical region was lower than 0.15mm. This result was consistent with the findings of a study that concluded that NiTi rotary files could be more effective in preparing canals with narrow apical diameters.²¹

There is no definitive idea in the literature about the amount of dentin removal to provide the best disinfection of the root canal but, it is emphasized that the excessive dentin removal can increase the risk of perforations.²²⁻²⁵ In this study, EndoArt rotary files removed more dentin compared to K-files in coronal and middle third of the root canals. This results was similar with the previous studies which reported greater dentin removal using a rotary files in primary teeth.^{24,26} On the other side, some studies found that dentin removal was greater when using conventional hand files.^{22,23,25} Barr et al. reported that the use of rotary files for root canal shaping has advantages such as more effective and faster removal of tissue and debris, easier access to canals, and conical shaped canals that allow a more effective canal filling.⁷ In addition, EndoArt can effectively produce a well tapered root canal form than conventional K file.

In pediatric dentistry, the length of the treatment had an essential influence on the child patient's anxiety, so the instrumentation time during canal preparation is the topic of many studies.^{11,27-29} Most studies indicated shorter instrumentation time with rotary files compared with conventional hand files.^{13,28-30} But in the present study, the instrumentation time was found similar for the K file and EndoArt rotary file. The result may be related with the operator's experience and the

tooth used in the previous studies being a primary or permanent tooth.^{31,32} In authors' opinion, although the number of files is the same, the time spent in file change in the rotary file system is also a factor to be considered. The limitation of the study was the criteria of tooth selection. Among the primary tooth extraction indications, there are teeth that are too damaged for conservative or endodontic treatment, teeth with more than 1/3 radiolucency in their bifurcation and mobile teeth with extensive root resorption. It is difficult to find non-resorbed roots of extracted primary tooth so in previous in-vitro studies, different primary teeth were used. Especially, primary molar teeth were chosen. In present study, standardization has been tried to be achieved with the same root length, number of canals and curvature similar with the previous literature.^{21,33,34}

In future studies, resin teeth which are produced using three-dimensional technology can be chosen for the standardization but, the real canals of human primary teeth were selected for current study because of the similarity in canal cross-section, the dentin hardness and its surface texture to clinical condition.

Within the limitations of our study, according to the authors of this study, the use of EndoArt systems in primary teeth provides the shape of the root canal is more conical. As a result of the conical root canal, better quality root canal fillings can increase clinical success

ACKNOWLEDGMENT

The authors thank Inci Dental for providing endodontic instruments.

CONFLICT OF INTERESTS

No potential conflict of interest relevant to this article was reported.

REFERENCES

1. McDonald RE, Avery DR DJ. Dentistry for the child and adolescent. 7th ed. St. Louis: CV Mosby Co; 2000.
2. Fuks AB, Guelmann M, Kupietzky A. Current developments in pulp therapy for primary teeth. *Endod Top*. 2010;23:50-72.
3. Sharma P, Kurthukoti AJ, Swamy DF, Shashidara R, Swamy EB. Computed tomographic morphometry of the internal anatomy of mandibular second primary molars. *Int J Clin Pediatr Dent*. 2015;8(3):202-7.
4. Fumes AC, Sousa-Neto MD, Leoni GB, Versiani MA, da Silva LAB, da Silva RAB, et al. Root

- canal morphology of primary molars: a micro-computed tomography study. *Eur Arch Paediatr Dent.* 2014;15:317–26.
5. Kandaswamy D, Venkateshbabu N, Porkodi I, Pradeep G. Canal-centering ability: an endodontic challenge. *J Conserv Dent.* 2009;12(1):3–9.
6. Silva LAB, Leonardo MR, Nelson-Filho P, Tanomaru JMG. Comparison of rotary and manual instrumentation techniques on cleaning capacity and instrumentation time in deciduous molars. *J Dent Child.* 2004;71:45–7.
7. Barr ES, Kleier DJ, Barr N V. Use of nickel-titanium rotary files for root canal preparation in primary teeth. *Pediatr Dent.* 2000;22(1):77–8.
8. Manchanda S, Sardana D, Yiu CKY. A systematic review and meta-analysis of randomized clinical trials comparing rotary canal instrumentation techniques with manual instrumentation techniques in primary teeth. *Int Endod J.* 2020;5(3):333–53.
9. Drukteinis S BI. A scanning electron microscopic study of debris and smear layer remaining following use of AET instruments and K-flexofiles. *Stomatologija.* 2006;8:70–5.
10. Panchal V, Jeevanandan G, Subramanian EMG. Comparison of instrumentation time and obturation quality between hand K-file, H-files, and rotary Kedo-S in root canal treatment of primary teeth: A randomized controlled trial. *J Indian Soc Pedod Prev Dent.* 2019;37(1):75.
11. Priyadarshini P, Jeevanandan G, Govindaraju L, Subramanian EMG. Clinical evaluation of instrumentation time and quality of obturation using paediatric hand and rotary file systems with conventional hand K-files for pulpectomy in primary mandibular molars: a double-blinded randomized controlled trial. *Eur Arch Paediatr Dent.* 2020;1–9.
12. EndoArt Ni-Ti Gold Pedo Kit. <http://www.incidental.com.tr/uploads/urun/pdf/endoart-action-gold-rotary-files1583257168.pdf>.
13. Musale PK, Mujawar SAV. Evaluation of the efficacy of rotary vs. hand files in root canal preparation of primary teeth in vitro using CBCT. *Eur Arch Paediatr Dent.* 2014;15(2):113–20.
14. Gambill JM, Alder M del RC. Comparison of nickel-titanium and stainless steel hand-file instrumentation using computed tomography. *J Endod.* 1996;22:369–75.
15. Hasheminia SM, Farhad A, Sheikhi M, Soltani P, Hendi SS, Ahmadi M. Cone-beam computed tomographic analysis of canal transportation and centering ability of single-file systems. *J Endod.* 2018;44:1788–791.
16. Hashem AAR, Ghoneim AG, Lutfy RA, Foda MY, Omar GAF. Geometric analysis of root canals prepared by four rotary NiTi shaping systems. *J Endod.* 2012;38(7):996–1000.
17. Bernardes RA, Rocha EA, Duarte MAH, Vivan RR, Gomes De Moraes I, Bramante AS, et al. Root canal area increase promoted by the EndoSequence and ProTaper systems: comparison by computed tomography. *J Endod.* 2010;36(7):1179–182.
18. Elsherief SM, Zayet MK, Hamouda IM. Cone-beam computed tomography analysis of curved root canals after mechanical preparation with three nickel-titanium rotary instruments. *J Biomed Res.* 2013;27(4):326–33.
19. Ahmed HMA. Anatomical challenges, electronic working length determination and current developments in root canal preparation of primary molar teeth. *Int Endod J.* 2013;46:1011–22.
20. Peters OA. Current challenges and concepts in the preparation of root canal systems: a review. *J Endod.* 2004;30(8):559–67.
21. Esentürk G, Akkas E, Cubukcu E, Nagas E, Uyanik O, Cehreli ZC. A micro-computed tomographic assessment of root canal preparation with conventional and different rotary files in primary teeth and young permanent teeth. *Int J Paediatr Dent.* 2020;30:202–8.
22. Radhika E, Reddy ER, Rani ST, Kumar LV, Manjula M, Mohan TA. Cone beam computed tomography evaluation of hand nickel-titanium K-files and rotary system in primary teeth. *Pediatr Dent.* 2017;39:319–23.
23. Kaya E, Elbay M, Yiğit D. Evaluation of the self-adjusting file system (SAF) for the instrumentation of primary molar root canals: a micro-computed tomographic study. *Eur J Paediatr Dent.* 2017;18:105–10.
24. Selvakumar H, Kavitha S, Thomas E, Anadhan V, Vijayakumar R. Computed tomographic evaluation of K3 rotary and stainless steel K file instrumentation in primary teeth. *J Clin Diagnostic Res.* 2016;10:ZC05–08.
25. Kummer TR, Calvo MC, Cordeiro MMR, de Sousa Vieira R, de Carvalho Rocha MJ. Ex vivo study of manual and rotary instrumentation techniques in human primary teeth. *Oral Surg Oral Med Oral Pathol Oral Radiol Endodontology.* 2008;105:84–92.
26. Poornima P, Disha P, Nagaveni NB, Roopa KB, Bharath KP, Neena IE. Volumetric analysis of hand and rotary root canal instrumentation and filling in primary teeth using Spiral Computed Tomography - an invitro study. *Int J Paediatr Dent.* 2016;26:193–8.
27. Rosa FM, Modesto A F-JI. Manual and rotary instrumentation techniques for root canal preparation in primary molar. *Dentistry.* 2014;2:1–5.
28. Pinheiro SL, Araujo G, Bincelli I, Cunha R, Bueno C. Evaluation of cleaning capacity and instrumentation time of manual, hybrid and rotary instrumentation techniques in primary molars. *Int Endod J.* 2012;45:379–85.

29. Nagaratna PJ, Shashikiran ND, Subbareddy V V. In vitro comparison of NiTi rotary instruments and stainless steel hand instruments in root canal preparations of primary and permanent molar. *J Indian Soc Pedod Prev Dent.* 2006;24:186–91.
30. Govindaraju L, Jeevanandan G, Subramanian EMG. Comparison of quality of obturation and instrumentation time using hand files and two rotary file systems in primary molars: a single-blinded randomized controlled trial. *Eur J Dent.* 2017;11:376–9.
31. Madan N, Rathnam A, Shigli AL, Indushekar KR. K-file vs ProFiles in cleaning capacity and instrumentation time in primary molar root canals: An in vitro study. *J Indian Soc Pedod Prev Dent.* 2011;29(1):2–6.
32. Yared GM, Bou Dagher FE, Machtou P. Influence of rotational speed, torque and operator's proficiency on ProFile failures. *Int Endod J.* 2001;34(1):47–53.
33. Deshpande AN, Joshi NH, Naik KS. In vitro comparative evaluation of cleaning efficacy and volumetric filling in primary molars: Cone beam computed tomography evaluation. *Contemp Clin Dent.* 2017;8(1):33.
34. Shaikh SM, Goswami M. Evaluation of the effect of different root canal preparation techniques in primary teeth using CBCT. *J Clin Pediatr Dent.* 2018;42(4):250-5.

(Received January 18, 2021; Accepted July 16, 2021)