

8-30-2015

An Auto-fluorescence Guided Surgical Approach Performed with Er:YAG Laser and Nd:YAG Low Level Laser Therapy for Medication-related Osteonecrosis of the Jaw

Ilaria Giovannacci,

Department of Biomedical, Biotechnological and Translational Sciences–Center of Oral Pathology and Laser Surgery, University of Parma, Via Gramsci, Parma 14-43100, ilaria.giovannacci@gmail.com

Marco Meleti

Department of Biomedical, Biotechnological and Translational Sciences–Center of Oral Pathology and Laser Surgery, University of Parma, Via Gramsci, Parma 14-43100, marcomeleti@gmail.com

Mauro Bonanini

Department of Biomedical, Biotechnological and Translational Sciences–Center of Oral Pathology and Laser Surgery, University of Parma, Via Gramsci, Parma 14-43100, Italy., mauro.bonanini@unipr.it

Paolo Vescovi

Department of Biomedical, Biotechnological and Translational Sciences–Center of Oral Pathology and Laser Surgery, University of Parma, Via Gramsci, Parma 14-43100, Italy., paolo.vesc@gmail.com

Follow this and additional works at: <https://scholarhub.ui.ac.id/jdi>

Recommended Citation

Giovannacci, I., Meleti, M., Bonanini, M., & Vescovi, P. An Auto-fluorescence Guided Surgical Approach Performed with Er:YAG Laser and Nd:YAG Low Level Laser Therapy for Medication-related Osteonecrosis of the Jaw. *J Dent Indones.* 2015;22(2):

This Case Report is brought to you for free and open access by the Faculty of Dentistry at UI Scholars Hub. It has been accepted for inclusion in Journal of Dentistry Indonesia by an authorized editor of UI Scholars Hub.

CASE REPORT

An Auto-fluorescence Guided Surgical Approach Performed with Er:YAG Laser and Nd:YAG Low Level Laser Therapy for Medication-related Osteonecrosis of the Jaw

Ilaria Giovannacci, Marco Meleti, Mauro Bonanini, Paolo Vescovi

Department of Biomedical, Biotechnological and Translational Sciences—Center of Oral Pathology and Laser Surgery, University of Parma, Via Gramsci, Parma 14-43100, Italy.
Correspondence e-mail to: ilaria.giovannacci@gmail.com

ABSTRACT

Medication-Related Osteonecrosis of the Jaw (MRONJ) therapy remains an unresolved problem. The proposed conservative and surgical treatment regimens are associated to contradictory success rates. Surgical approach with Er:YAG laser is associated to significant better results compared to medical treatment and traditional surgical approaches. **Objective:** To describe a new surgical approach that couples the advantages of the Er:YAG laser and the usefulness of the AF in highlighting surgical margins. One of the difficulties encountered during surgical removal of a MRONJ is the precise individuation of necrotic bone margins. **Case Report:** A case of Stage III mandibular osteonecrosis treated with a new surgical approach is presented. The aim is to describe an auto-fluorescence (AF) guided surgical approach performed with Er:YAG laser and Nd:YAG Low Level Laser Therapy (LLLT). After one month of follow-up, the complete mucosal healing was evident and symptoms was unobserved. Such a technique allowed a highly accurate and minimally invasive approach through the selective ablation of the non-/hypo-fluorescent areas. **Conclusion:** Taking into account the advantages of laser therapy and the possible effectiveness of the AF in highlighting surgical margins, this approach would probably achieve excellent outcomes.

INTRODUCTION

Bisphosphonates-related osteonecrosis of the jaws (BRONJ) was defined in 2007 as an area of exposed bone in the maxillofacial region that does not heal within eight weeks after identification by a health care provider in a patient who received bisphosphonates therapy (BPT) and had not received radiation therapy to the craniofacial region.^{1,2}

In order to accommodate the growing number of osteonecrosis cases associated with other anti-resorptive and anti-angiogenic therapies, the American Association of Oral and Maxillofacial Surgeons (AAOMS) with a Position Paper in May 2014, changed the term in “Medication-Related Osteonecrosis of the Jaws” (MRONJ).³

According to the new definition, a patient may be considered affected with MRONJ if all the following

features are present: (1) current or previous treatment with anti-resorptive or anti-angiogenic agents; (2) exposed bone or bone that can be probed through an intraoral or extraoral fistula(e) in the maxillofacial region that has persisted for more than eight weeks; and (3) no history of radiation therapy to the jaws or obvious metastatic disease to the jaws.

To the best of our knowledge, there is no agreement on the management of such disorder and the success rates related to the different proposed protocols are very different and sometimes controversial.^{4,5}

Many different therapeutic approaches have been reported such as anti-microbial rinses, antibiotics, Low Level Laser Therapy (LLLT), local debridement and surgical resection performed through different devices, or a combination of these two treatments. As

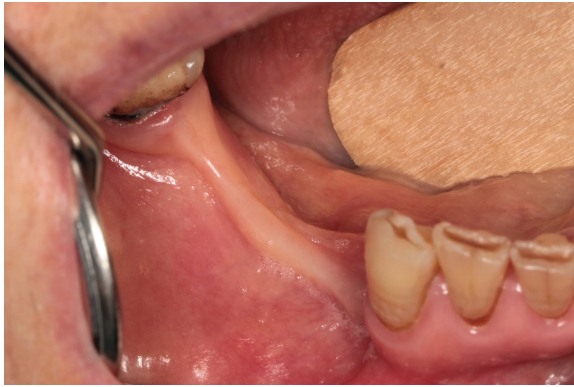


Figure 1. Intra-operative view showing a non-exposed stage II osteonecrosis

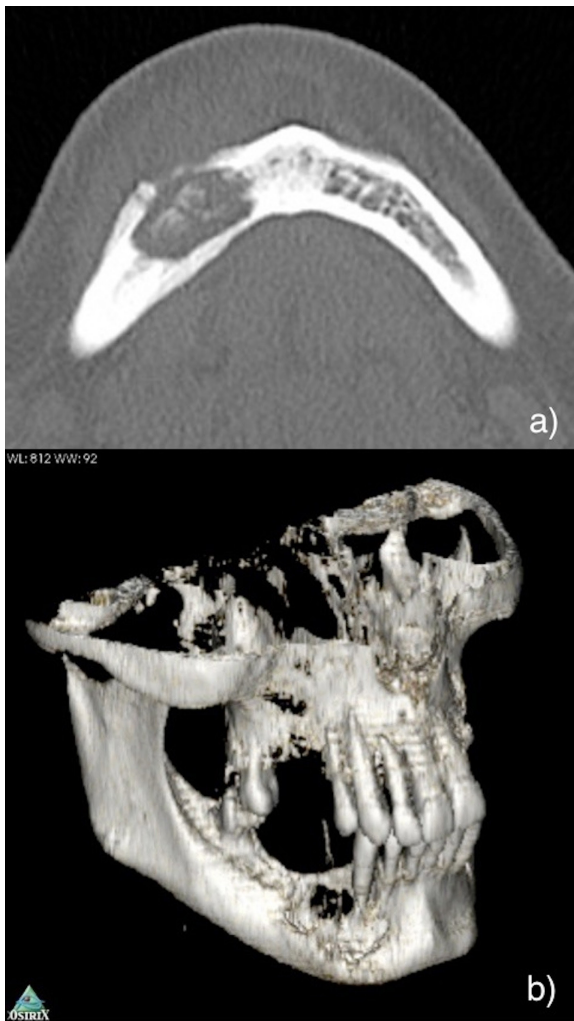


Figure 2. Computed Tomography (CT) scan (A) and 3D reconstruction (B) showing an osteonecrosis that involve vestibular and lingual plates

reported in recent reviews, the success rate for surgical approaches are approximately 80%.^{6,7} Particularly, results obtained with Er:YAG laser-assisted surgical approaches are significantly better than those obtained through traditional surgery.^{8,9}

It is worthy to mention here that Rupel *et al.* in a systematic review had reported complete healing

rates (HR) for nonsurgical approaches were 33% in Stage 1, 24% in Stage 2 and 0% in Stage 3; HR for conservative surgical approaches were 72% in Stage 1, 79% in Stage 2, and 27% in Stage 3; HR for extensive surgical approaches were 89% in Stage 0, 87% in Stage 1, 96% in Stage 2, and 81% in Stage 3 and 100% in Stage 1, 83% in Stage 2, 100% in Stage 3 for laser surgical approaches performed through Er:YAG and Er, Cr: YSGG lasers.⁶

One of the most frequent difficulty encountered during the surgical removal of MRONJ is the precise individuation of necrotic bone margins, usually based on vascularization, colour and texture of the bone.^{10,11} Some authors proposed the use of fluorescence tetracycline-induced in order to discriminate necrotic from viable bone. Due to its affinity to calcium, tetracycline is incorporated into the remodelling and apposition areas of the bone.^{12,13} It is then incorporated into viable but not into necrotic bone and can be visualized by an excitation light of 390 to 430 nm.^{14,15}

Ristow and Pautke in a recent technical note suggested that even in the absence of tetracycline labelling, the vital bone could be highlighted on the basis of its Auto-Fluorescence (AF). Necrotic bone which is lost AF, appears very dark.¹⁶ This condition is possibly caused by alterations in the extracellular calcified osteoid matrix or in the bone cells of the necrotic tissue, but the specific mechanism has not yet been investigated.¹⁶

The aim of this paper is to describe a new surgical approach that couples the advantages of the Er:YAG laser and the usefulness of the AF in highlighting surgical margins.

CASE REPORT

A 65-year old female patient was affected by osteoporosis for which she received 84 doses *im* of Alendronic acid. The patient was diagnosed with a Stage 2 non-exposed osteonecrosis (according to the AAOMS 2014 staging system) on the right mandible (Figure 1). Dental anamnesis revealed the extraction of the premolars and the first molar in the same area four months before. Computed tomography (CT) scans and the 3D reconstruction showed a necrosis involving the vestibular and lingual plates (Figure 2A and B).

Surgical technique

The surgical treatment was performed under local anaesthesia. Antibiotic therapy with amoxicillin (2 gram/day) and metronidazole (1 gram/day) was administered from three days before to three weeks after intervention. No preoperative tetracycline labelling was performed.

After mucoperiosteal flap was performed for affected bone exposure, the VELscope™ (LED Medical

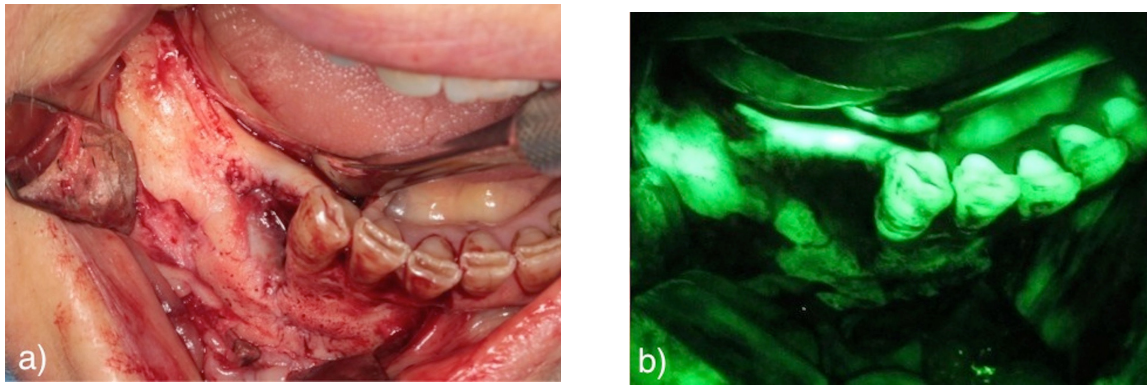


Figure 3. A. Clinical photograph of the mucoperiosteal flap of the necrotic area; B. Visualization of the mandibular bone using VELscopeTM (LED Medical Diagnostics Inc., Barnaby, Canada) showed no or only pale AF

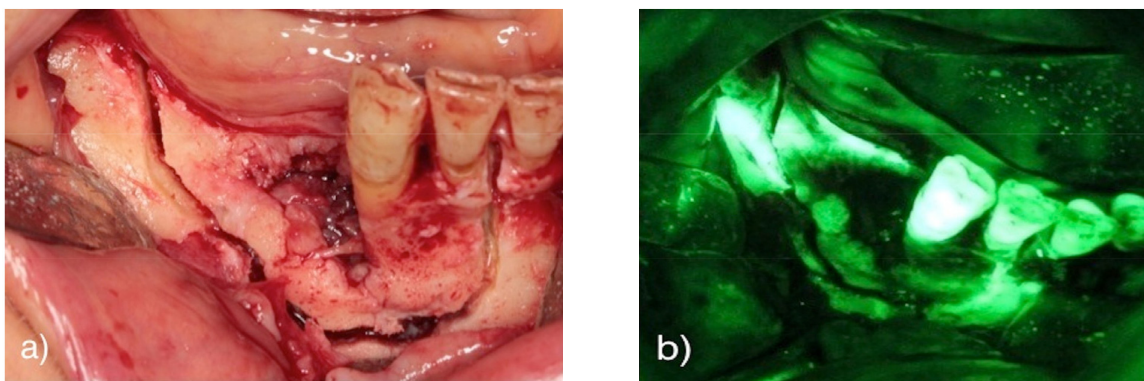


Figure 4. Surgical field after mucoperiosteal flap elevation: A) necrotic bone B) Auto-fluorescence (AF) image showing hypo-fluorescent (dark) area

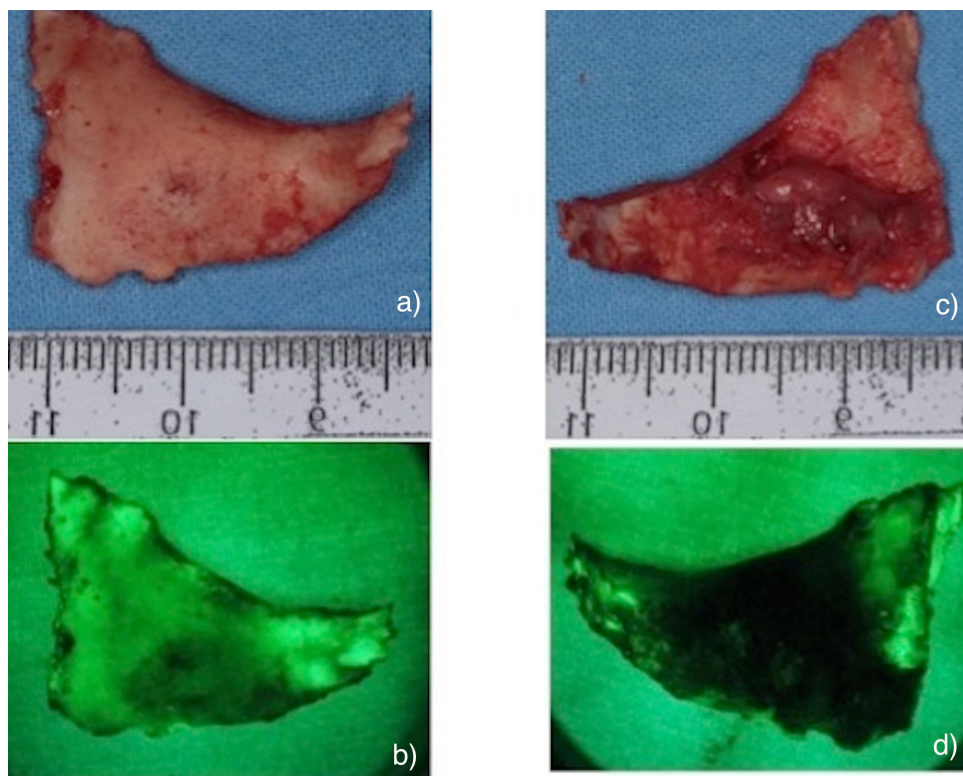


Figure 5. 5A,B. Clinical photograph and its AF visualization of the vestibular surface of the removed bone; 5B,C. Clinical photograph and its AF visualization of the lingual surface of the removed bone showed hyper fluorescent borders

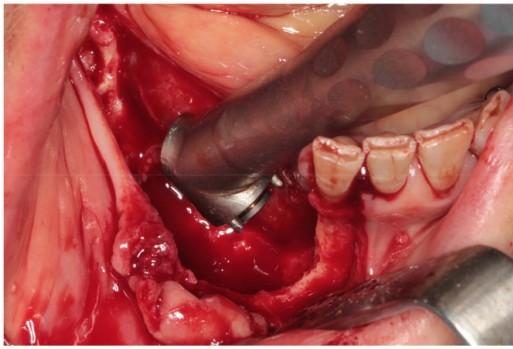


Figure 6. Er:YAG laser evaporation generates bone micro-perforations in order to stimulate vascularization and promote healing and attachment of the soft tissue

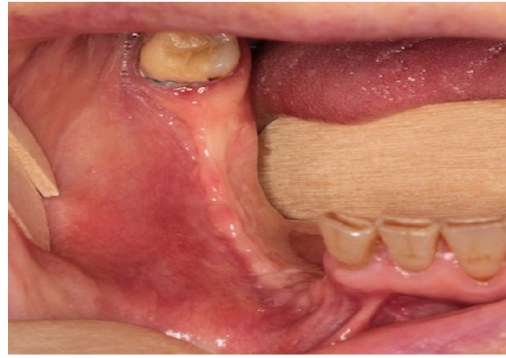


Figure 7. Clinical photograph at one month after surgery showed complete mucosal healing

Diagnostics Inc., Barnaby, Canada) system was used to induce and visualize AF of the mandibular bone. It was evident that necrotic bone areas showed no or only pale AF (Figure 3A and B). Osteotomy was performed through Lindeman bur (Figure 4A and B).

After the removal of the necrotic bone block, AF visualization was used to guide the marginal bone osteoplasty (Figure 5). A traditional ball-shaped bur was used to remove sharp angles of the bone due to its minimum effect on the soft tissues.

According to the AF image obtained after osteoplasty, Er:YAG laser (Fidelis Plus®, Fotona - Slovenia) (Parameters: 300 mJ, 30 Hz, fluence of 60 J/cm²) was used for the vaporization of necrotic bone and for the detection of healthy bone (Figure 6). This laser is useful in the removal of additional minimal bone after osteoplasty. Its action produces micro-spots on the bone surface for vascularization and promoting healing and attachment of the soft tissue.^{25,26}

Moreover, through the minimally invasive action typical of this device, it is possible to act in the areas where non-fluorescence or hypo-fluorescence has been displayed.

The patient received an intra-operative irrigations with povidone iodine solution 10% and application of low level laser therapy (LLLT) (Nd:YAG laser, 1064 nm, Fidelis Plus, Fotona®, Slovenia – power: 1.25 W; frequency: 15 Hz; diameter of the fibre: 320 µm) which was administered in non-focused mode, at 2 mm of distance from the tissues for 1 minute (power density: 1562.5 W/cm², fluence 7 J/cm²), five times. A tension-free wound closure was achieved using continuous locked suture. The patient received weekly applications of LLLT for three weeks after intervention.

After one month, the complete mucosal healing was evident and there was no symptom observed (Figure 7).

DISCUSSION

The identification of necrotic bone margins during osteonecrosis removal is a major difficulty for surgeons. Until now detection of necrosis has been solely based on radiological diagnostic images (e.g. CT scans, nuclear magnetic resonance), and on subjective parameters including the colour, texture and bleeding of the affected bone.^{19,20} Some studies reported that bone bleeding is not always correlated with histological findings of vital bone.⁵

The VELscope™ device is a non-invasive tool designed as a first level diagnostic aid for increasing the diagnostic accuracy (DA) and enhance the specificity (SP) and sensitivity (SE) of the conventional oral examination in detecting early mucosal changes. VELscope™ emits light in the blue spectrum (400-460 nm) that excites natural fluochromes located within the epithelium and the submucosa. Fluochromes of the normal tissues show an AF in the range of the green colour; while displastic tissues associated with a loss of autofluorescence (LAF), appear dark in contrast to the surrounding area.^{21,22}

A similar effect of LAF has been recently shown in necrotic bone.^{13,16} Ristow and Pautke speculated that such a fluorescence could be caused by alterations in the extracellular calcified osteoid matrix or in the bone cells.¹⁶ In the present observation, viable bone seems to emit a very bright AF, in contrast, a LAF seems to be present in areas of necrotic bone in patients affected with MRONJ. Consequently, Direct Visual Intra-operative Fluorescence Examination (DVIFE) seems to be a suitable guide to visualize necrotic bone during surgical debridement/resection. DVIFE as a guide to detect surgical margins of MRONJ is not invasive, easy to apply and independent from the subjective impression of the surgeon differently from the analysis of the clinical appearance of bone and radiological features.

The VELscope™ DVIFE uses the AF principles and therefore pre-operative administration of tetracyclines, as proposed by some researcher, is not necessary. Due to its affinity to calcium, tetracycline is incorporated into the remodelling and apposition areas of bone. Therefore, it is incorporated into viable but not into necrotic bone and can be visualized using an excitation light of 390 to 430nm.²³ Such fluorescence is not the AF from the bone but apparently it comes from tetracycline.

The surgical technique described in this paper associates the usefulness of the AF in highlighting surgical margins with the advantages of the Er:YAG laser. The Er:YAG laser beam (wavelength: 2.940nm) is highly absorbed by major components of bone, such as organic matrix and inorganic calcium salts. Er:YAG laser is used with distilled water irrigation system and air spray. It does not produce coagulation or carbonization. Such feature reduces the thermal damage on bone and the adjacent tissue. Each spot of the laser induces a vaporization of 0.1mm of tissue, achieving a gradual and safe ablation of the necrotic areas until reaching healthy bleeding bone. Particularly, the minimally invasive technique of bone evaporation is used to create micro-perforations in order to stimulate new vascularization and promote healing and attachment of the soft tissue on bone.^{17, 18}

The association of the Er:YAG laser and the AF is highly useful in the removal of additional minimal necrotic bone after osteoplasty. It is possible to apply laser evaporation in the areas where non-fluorescence or hypo-fluorescence has been displayed. Moreover, biological advantages of Er:YAG surgery, such as bactericidal and biostimulative actions are valuable points in MRONJ surgery.^{17,18}

These properties are further enhanced by Nd:YAG LLLT that causes a bio-modulation of soft and hard tissues consisting of different effects, particularly anti-inflammatory, bio-stimulating, anti-bacterial and analgesic.²⁴ The bio-stimulating effect acts on the immune system and on the collagen tissue, increases proliferation and activity of fibroblasts, enhances cellular turnover on the epithelial tissue and ameliorate proliferation and activity of osteoblasts.^{9,10} The anti-inflammatory effect is achieved by the increase of the microcirculation, the reduction of the oedema and by the suppressed production of prostaglandins, interleukin-1 (IL-1) and tumour necrosis factor-alpha (TNF- α).²⁴ The analgesic effect is achieved through two mechanisms: indirect mechanism associated to the anti-inflammatory effects, and one direct mechanism against the nervous system. Particularly, the laser causes a hyperpolarization of the axonal membrane blocking the passage of the nervous impulse.²⁴ All these features help to promote healing of bone and soft tissue and to improve the postoperative course and patient's quality of life.

CONCLUSION

This case report shows that Er:YAG laser therapy has more biological advantages compared to conventional surgery that would allow the operator to achieve excellent outcomes for the patient healing process.

REFERENCES

1. Marx RE. Pamidronate (Aredia) and zoledronate (Zometa) induced avascular necrosis of the jaws: a growing epidemic. *J Oral Maxillofac Surg.* 2003;61:115-8.
2. Khosla S, Burr D, Cauley J, Dempster DW, Ebeling PR, et al. Bisphosphonate associated osteonecrosis of the jaw: report of a Task Force of the American Society of Bone and Mineral Research (ASBMR). *J Bone Miner Res.* 2007;22:1479-91.
3. Ruggiero SL, Dodson TB, Fantasia J, Goodday R, Aghaloo T, et al. American Association of Oral and Maxillofacial Surgeons position paper on medication-related osteonecrosis of the jaw--2014 update. *J Oral Maxillofac Surg.* 2014;72:1938-56.
4. Vescovi P. Bisphosphonates and osteonecrosis: an open matter. *Clin Cases Miner Bone Metab.* 2012;9:142-4.
5. Ristow O, Otto S, Troeltzsch M, Hohlweg-Majert B, Pautke C. Treatment perspectives for medication-related osteonecrosis of the jaw (MRONJ). *J Craniomaxillofac Surg.* 2015;43:290-293.
6. Rupel K, Ottaviani G, Gobbo M, Contardo L, Tirelli G, et al. A systematic review of therapeutical approaches in bisphosphonates-related osteonecrosis of the jaw (BRONJ). *Oral Oncol.* 2014;50:1049-57.
7. Fliefel R, Tröltzsch M, Kühnisch J, Ehrenfeld M, Otto S. Treatment strategies and outcomes of bisphosphonate-related osteonecrosis of the jaw (BRONJ) with characterization of patients: a systematic review. *Int J Oral Maxillofac Surg.* 2015;S0901-5027:00058-2.
8. Vescovi P, Manfredi M, Merigo E, Meleti M, Fornaini C, et al. Surgical approach with Er:YAG laser on osteonecrosis of the jaws (ONJ) in patients under bisphosphonate therapy (BPT). *Lasers Med Sci.* 2010;25:101-13.
9. Vescovi P, Merigo E, Meleti M, Manfredi M, Guidotti R, et al. Bisphosphonates-related osteonecrosis of the jaws: a concise review of the literature and a report of a single-centre experience with 151 patients. *J Oral Pathol Med.* 2012;41:214-21.
10. Montebugnoli L, Felicetti L, Gissi DB, Pizzigallo A, Pelliccioni GA, et al. Bisphosphonate-associated osteonecrosis can be controlled by nonsurgical management. *Oral Surg Oral Med Oral Pathol Oral Radiol Endod.* 2007;104:e473-7.
11. Pautke C, Bauer F, Tischer T, Kreutzer K, Weitz

- J, et al. Fluorescence-guided bone resection in bisphosphonate-associated osteonecrosis of the jaws. *J Oral Maxillofac Surg.* 2009;67:471-6.
12. Pautke C, Tischer T, Neff A, Horch HH, Kolk A. In vivo tetracycline labeling of bone: an intraoperative aid in the surgical therapy of osteoradionecrosis of the mandible. *Oral Surg Oral Med Oral Pathol Oral Radiol Endod.* 2006;102:e10-3.
13. Assaf AT, Zrnc TA, Riecke B, Wikner J, Zustin J, et al. Intraoperative efficiency of fluorescence imaging by Visually Enhanced Lesion Scope (VELscope) in patients with bisphosphonate related osteonecrosis of the jaw (BRONJ). *J Craniomaxillofac Surg.* 2014;42:e157-64.
14. Pautke C, Tischer T, Neff A, Horch HH, Kolk A. *In vivo* tetracycline labeling of bone: An intraoperative aid in the surgical therapy of osteoradionecrosis of the mandible. *Oral Surg Oral Med Oral Pathol Oral Radiol Endod.* 2006;102:e10.
15. Harvey BR, Ephros H, Defalco RJ. Tetracycline bone labeling in surgical management of chronic osteomyelitis: A case report. *J Oral Maxillofac Surg.* 2004;62:752.
16. Ristow O, Pautke C. Auto-fluorescence of the bone and its use for delineation of bone necrosis. *Int J Oral Maxillofac Surg.* 2014; 43:1391-3.
17. Pourzarandian A, Watanabe H, Aoki A, Ichinose S, Sasaki KM, et al. Histological and TEM examination of early stages of bone healing after Er:YAG laser irradiation. *Photomed Laser Surg.* 2004;22:342-50.
18. Pourzarandian A, Watanabe H, Ruwanpura SM, Aoki A, Ishikawa I. Effect of low-level Er:YAG laser irradiation on cultured human gingival fibroblasts. *J Periodontol.* 2005;76:187-93.
19. Bedogni A, Fedele S, Bedogni G, Scoletta M, Favia G, et al. Staging of osteonecrosis of the jaw requires computed tomography for accurate definition of the extent of bony disease. *Br J Oral Maxillofac Surg.* 2014; 52:e603-8.
20. Pautke C, Bauer F, Otto S, Tischer T, Steiner T, et al. Fluorescence-guided bone resection in bisphosphonate-related osteonecrosis of the jaws: first clinical results of a prospective pilot study. *J Oral Maxillofac Surg.* 2011;69:84-91.
21. Bhatia N, Matias MA, Farah CS. Assessment of a decision making protocol to improve the efficacy of VELscope™ in general dental practice: a prospective evaluation. *Oral Oncol.* 2014;50:1012-9.
22. McNamara KK, Martin BD, Evans EW, Kalmar JR. The role of direct visual fluorescent examination (VELscope) in routine screening for potentially malignant oral mucosal lesions. *Oral Surg Oral Med Oral Pathol Oral Radiol.* 2012;114:636-43.
23. Fleisher KE, Doty S, Kottal S, Phelan J, Norman RG, et al. Tetracycline- guided debridement and cone beam computed tomography for the treatment of bisphosphonate-related osteonecrosis of the jaw: a technical note. *J Oral Maxillofac Surg.* 2008;66:2646-53.
24. Giovannacci I, Mergoni G, Meleti M, Merigo E, Fornaini C, et al. Postoperative discomfort in oral soft tissue surgery: a comparative perspective evaluation of Nd:YAG Laser, quantic molecular resonance scalpel and cold blade. *Minerva Stomatol.* 2015;64:9-20.

(Received July 14, 2015; Accepted August 12, 2015)