

June 2018

Erect Position as the Alternative Technique in Achilles Tendon US: Comparison with Prone Position

Lailatul Muqmiroh

Radiologic Technology Programme, Vocational Faculty, Airlangga University, Liling.sahadi@gmail.com

Safinah Fajarini Yusfadiyah

Radiologic Technology Programme, Vocational Faculty, Airlangga University, Safinahfy@gmail.com

Paulus Rahardjo

Radiology Department, Medical Faculty, Airlangga University, Msksoetomo.unair@gmail.com

Follow this and additional works at: <https://scholarhub.ui.ac.id/jvi>

Recommended Citation

Muqmiroh, Lailatul; Yusfadiyah, Safinah Fajarini; and Rahardjo, Paulus (2018) "Erect Position as the Alternative Technique in Achilles Tendon US: Comparison with Prone Position," *Jurnal Vokasi Indonesia*: Vol. 6: No. 1, Article 2.

Available at: <https://scholarhub.ui.ac.id/jvi/vol6/iss1/2>

This Article is brought to you for free and open access by the Vocational Education Program at UI Scholars Hub. It has been accepted for inclusion in Jurnal Vokasi Indonesia by an authorized editor of UI Scholars Hub.

Erect Position as the Alternative Technique in Achilles Tendon US: Comparison with Prone Position

Lailatul Muqmiroh¹, Safinah Fajarini Yusufadhiyah² and Paulus Rahardjo³

1. dan 2. Radiologic Technology Programme, Vocational Faculty, Airlangga University

3. Radiology Department, Medical Faculty, Airlangga University

Email: *Liling.sahadi@gmail.com, Safinahfy@gmail.com, Msksoetomo.unair@gmail.com

Diterima : 15 Mei 2017

Layak Terbit : 1 Januari 2018

Abstract

Background : Ultrasonography (US) is the cheaper and non invasive modality to determine Achilles tendon. Prone position is the standart position of Achilles tendon US. However, it is a discomfort for an uncooperative patient and a difficult technique too. The erect position is an alternative technique of Achilles tendon US. The goal of this study is to compare the erection as an alternative position with prone as a standart position.

Material and Methode: The patient who had an injury or any inflammation process of Achilles tendon were excluded. The patient underwent two positions of Achilles tendon US, 900 and dorsoflexi. Longitudinal axis measured tendon thickness and a transversal axis which covered a cross-sectional area of the tendon.

Result: From all the 21 patients coming, 13 patients were males (61,9%), and eight patients were females (38,1%). The mean of tendon thickness and cross-sectional area in 900 prone positions were 4,24±0,24 mm, 30,08±2,86 mm, respectively. The mean of tendon thickness and cross-sectional area in 900 erect positions were 4,27±0,23 mm, 31,36±2,19 mm, respectively. There was no anisotropy effect during longitudinal axis examination. Conclusion: We found that there were no significant differences between a prone and erect position (p<0.05). The erect postion could be an alternative position, uncooperative patient in particular, without reducing the diagnostic value.

Keywords: Achilles tendon the US, erect position, prone position, tendon thickness, cross-sectional area

Abstrak

Posisi Ereksi sebagai Alternatif Teknik di Achilles Tendon US:Perbandingan dengan Posisi Rawan.
Latar Belakang: Ultrasonografi (AS) adalah modalitas yang lebih murah dan tidak invasif untuk menentukan tendon Achilles. Posisi rawan adalah posisi standart Achilles tendon AS. Namun, ini adalah ketidaknyamanan bagi pasien yang tidak kooperatif dan teknik yang sulit juga. Posisi tegak adalah teknik alternatif Achilles tendon AS. Tujuan dari penelitian ini adalah untuk membandingkan ereksi sebagai posisi alternatif dengan rawan sebagai posisi standart.

Bahan dan Metoda: Pasien yang mengalami cedera atau proses inflamasi tendon Achilles dikeluarkan. Pasien tersebut menjalani dua posisi Achilles tendon AS, 900 dan dorsoflexi. Sumbu longitudinal diukur ketebalan tendon dan sumbu transversal yang meliputi luas penampang tendon.

Hasil: Dari 21 pasien yang datang, 13 pasien adalah laki-laki (61,9%) dan 8 pasien adalah perempuan (38,1%). Rata-rata ketebalan tendon dan luas penampang melintang pada posisi rawan 900 masing-masing adalah 4,24 ± 0,24 mm, 30,08 ± 2,86 mm. Rata-rata ketebalan tendon dan luas penampang melintang pada posisi 900 tegak masing-masing adalah 4,27 ± 0,23 mm, 31,36 ± 2,19 mm. Tidak ada efek anisotropi selama pemeriksaan sumbu longitudinal. Kesimpulan: Kami menemukan bahwa tidak ada perbedaan yang signifikan antara posisi rawan dan ereksi (p <0,05). Posisi ereksi bisa menjadi posisi alternatif, pasien yang tidak kooperatif pada khususnya, tanpa mengurangi nilai diagnostik.

Keywords: Achilles tendon AS, posisi tegak, posisi rawan, ketebalan tendon, penampang melintang

INTRODUCTION

Achilles tendon is the largest and strongest tendon in the human body, but it is also mostly affected by trauma. Trauma to the Achilles tendon is usually

associated with poor flexibility and strability of ankle and also over the use of them.

Currently, Ultrasound (US) musculoskeletal is the choice for the patient as a supporting diagnostic besides Magnetic Resonance Imaging (MRI), because

Ultrasound (US) musculoskeletal is cheap, not invansive and it can be done quickly. In clinical practice, ultrasound musculoskeletal is widely accepted and developed in Europe and United States Standard position for assuring the ultrasound (US) of the Achilles tendon is anatomically in a prone position or standard 900 If this position is in the relatively long period, it will cause discomfort, distress to the patient and difficult in technique. The patients will suffer those bad cause; moreover, to the patients with certain clinical conditions.

MATERIALS AND METHODS

There are a total of 21 healthy patients being tested for their US Achilles tendon at Airlangga University Hospital. Every patient has examined for Achilles tendon US in prone position anatomically (900) and also dorsoflexi and in erect position anatomically (900) and also dorsoflexi. The inclusion criteria are that the patients: have never been experienced in inflammation, a trauma or structural abnormalities of the ankle area, the patients can be examined of US in the position of both prone and erect. The US examination used a US device of Siemens brand, Acuson X150 with a linear probe. Every position was done US examination by measuring the tendon thickness, transversal axis, wide and longitudinal axis. The data were analyzed by using a comparison test.

Examination technique with prone position.

All patients are tested for their US Achilles tendon in a 900 prone position and a dorsoflexi. At that 900 positions, the patient's feet were hanging over the end of the examination table, and the position of feet dorsiflexion rested on the examination table (Figure 1). The probe used is a linear probe with its depth of 4 mm, the probe placement area is parallel to the medial malleolus. The Achilles tendon will then be examined in a longitudinal axis, as a result of ultrasound, it is to be measured its tendon thickness which is also called diameter of Achilles tendon anteroposterior, the measurement is started by drawing a straight line from the upper limit of the tendon to the lower limit of the tendon. In the transverse incision, the extent area is measured, or it is called the circumference of a circle of the Achilles tendon (Figure 2,3,4,5). The measurement using the calliper menu – starts the area from the outer boundary line of the surrounding Achilles tendon.

Examination techniques in a standing (Erect) position.

It is similar to the prone position that all patients will be US checked at the 900 position and the dorsoflexi. In the 900 standard standing positions, the samples are instructed to stand upright on the step ladder or the top of the step ladder (Figure 1). The next step is to place the probe in a longitudinal slice to

examine the Achilles tendon thickness and to place the probe on the transversal slice to be examined the tendon extent area (Figure 6,7,8 and 9).

Statistical Analysis.

The consecutive (list of) data were displayed in the form of an average following its standard deviation. Data variation on the size of thickness and wideness of the Achilles tendon were analyzed with the independent variables, namely: the 900 standard prone positions, the dorsiflexion prone position, the 900 standard standing positions, and the standing dorsiflexion position. The data were tested using independent t test. Differences were considered significant when $P < 0.05$. The data were processed using SPSS 16.0 for Windows.

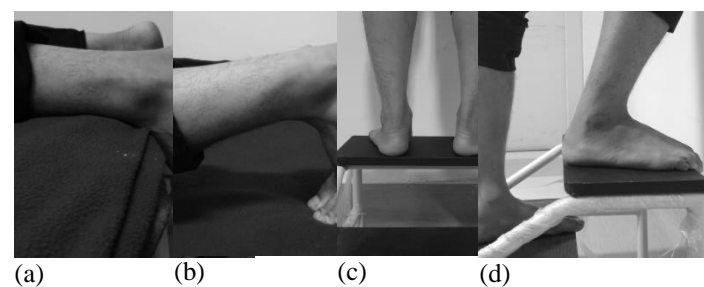


Figure 1. The checking position of the Achilles tendon

- The 90⁰ standard prone position
- The dorsoflexion prone position
- The 90⁰ standard standing position
- The dorsoflexion standing position

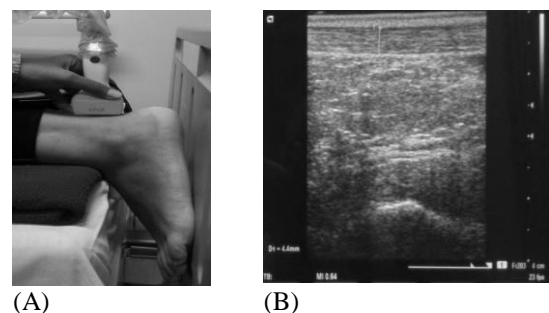


Figure 2 Position of the probe in Achilles tendon on a longitudinal axis with 90⁰ prone positions (A), the US result of Achilles tendon (B).

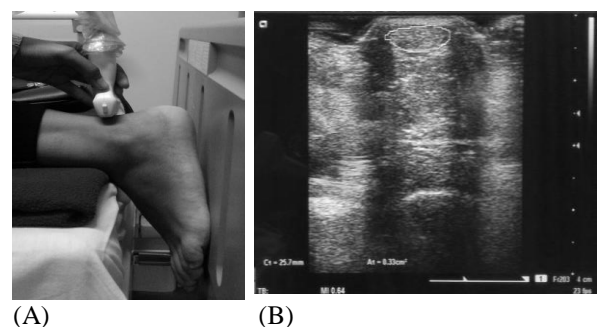


Figure 3. The position of the probe in *Achilles* tendon on transversal axis with 90° prone positions (A), the US result of *Achilles tendon* (B).

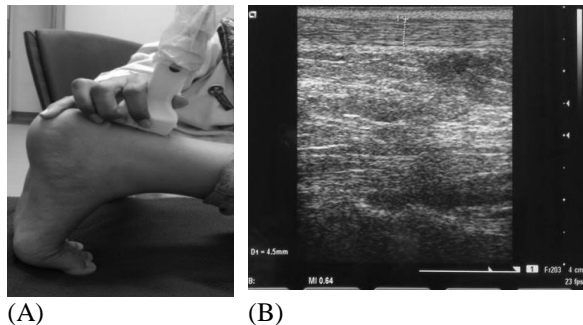


Figure 4. The position of the probe in *Achilles* tendon on a longitudinal axis with dorsoflexion prone position (A), the US result of *Achilles tendon* (B).

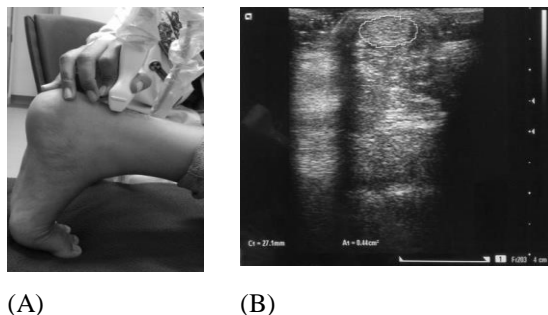


Figure 5. The position of the probe in *Achilles* tendon on transversal axis with dorsoflexion prone position (A), the US result of *Achilles tendon* (B).

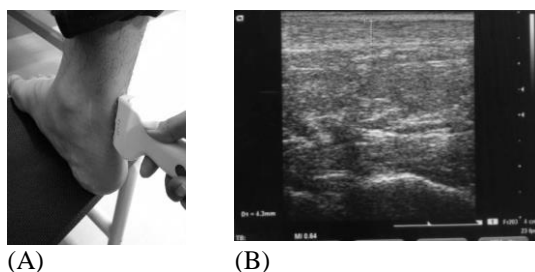


Figure 6. The position of the probe in *Achilles* tendon on a longitudinal axis with 90° erect positions (A), the US result of *Achilles tendon* (B).

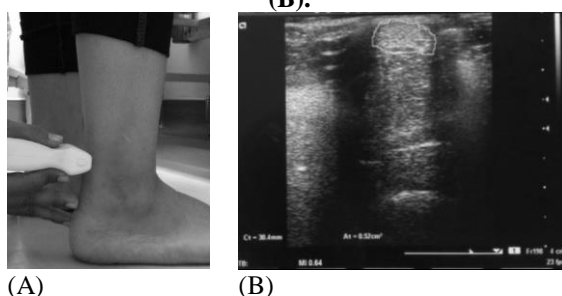


Figure 7. The position of the probe in *Achilles* tendon on transversal axis with 90° erect positions (A), the US result of *Achilles tendon* (B).

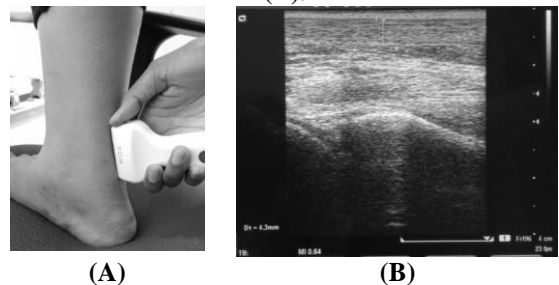


Figure 8. The position of the probe in *Achilles* tendon on a longitudinal axis with dorsoflexion erect position (A), the US result of *Achilles tendon* (B).

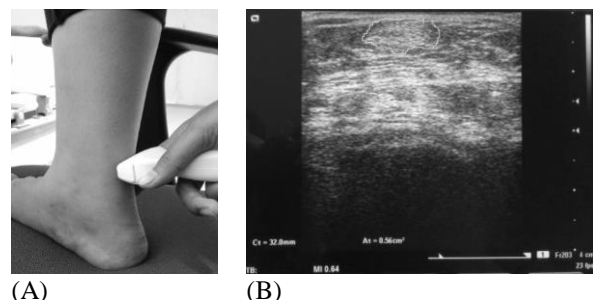


Figure 9. The position of the probe in *Achilles* tendon on transversal axis with dorsoflexion erect position (A), the US result of *Achilles tendon* (B).

RESULT AND DISCUSSION

Of all 21 patients who underwent the test consisted of 13 men (61.9%) and eight women (38.1%) with the mean of 21.9 y.o \pm 2.143. The mean of height and weight were 165.52 cm \pm 7.776 dan 63.38 kg \pm 12.294, respectively. In this study were not studied due to the effect of height and weight on the measurement results of the Achilles tendon. The result of the Achilles tendon measurement is shown in Table 1. The mean value or mean of the extent area of the Achilles tendon in the 900 standard prone positions is 30.08 \pm 2.86 mm, while in the 900 standard standing position, the values obtained are 31.36 \pm 2.19 mm. The mean value or mean of the extent area of the Achilles tendon in the dorsoflexion prone position is 31.51 \pm 2.33 mm, while in a dorsoflexion standing position the value obtained is of 32.08 \pm 2.28 mm.

Table 1. The measurements results of the Achilles tendon

	Thickness (mm)	Area wideness (mm ²)
Position		
90° Standar		
Prone	4,24 \pm 0,24	30,08 \pm 2,86
Standing	4,27 \pm 0,23	31,36 \pm 2,19
P	0,829	0,212

Dorsoflexion		
Prone	4,20±0,21	31,51±2,33
Standing	4,15±0,21	32,08±2,28
P	0,952	0,724

The Achilles tendon is the largest and the strongest tendon in the body. It is formed by the combined tendon of the gastrocnemius and soleus muscles (triceps surae). The Achilles tendon begins at the junction between gastrocnemius and soleus tendon in the middle of the calf.

Regarding morphology, normal Achilles tendon thickness should be no more than 8 mm in the dimensions of anteroposterior (AP), it becomes proximally thick and slightly tapers along the third distal for insertion on the calcaneal tubercle. The normal retrocalcaneal caudex should produce a radiolucen anterior to the distal fibers of insertion of the Achilles tendon which extends at least 2 mm below the superior surface of the calcaneus.

On the examination of the Achilles tendon, the previous patient is in a lying face downward, or in a prone, i.e. the patient's legs are dangling at the end of the examination table. The scan is performed on the Achilles tendon subsequently with a linear probe from the myotendinous junction until insertion calendar on the transversal and longitudinal area. The scanning is set at the medial level of the malleolus with the ultrasound probe is situated perpendicular to the Achilles tendon. In addition to the standard position, the dorsoflexion position will straighten the Achilles tendon to avoid anisotropy. The anisotropy is seen as an hypo-echoic focal area when the angle of the probe was not in 90 degrees on the structure depicted. It is easily found when the results of the Achilles tendon picture are as if the hypo-echoic which indicate pathological features up under the tendon.

In some people or certain conditions, the default position will cause the patient discomfort, and technically it will be difficult to be done as if there were a respiratory problem.

Modification of the ultrasound examination technique of the Achilles tendon is a new kind of research; there has been no similar study comparing the positioning techniques of Achilles tendon ultrasound. The Achilles tendon size obtained from this study is a new kind of innovation because there is

no specific reference to the size of the Achilles tendon for the Southeast Asian, especially Indonesian. The previous study by Pang in 2006 at The Hong Kong Polytechnic University discussed the size of thickness, wide area, and length of the Achilles tendon by age, weight and use of the dominant foot. technically it will be difficult to be done as if there were a respiratory problem.

Pang et al. found that the thickness and area wideness of the tendon with a lifespan of samples of 20 to 29 years, is 5.14 mm ± 0.57 and 57.80 mm² ± 11.61. While this study reveals that the Achilles tendon thickness on the 900 standards prone position is 4.24 mm ± 0.24, the area wideness of the Achilles tendon is 30.08 mm² ± 2.86. The result difference of the Achilles tendon measurement obtained by the research may have been influenced by specific factors, namely: race factors, height, weight, and feet activity which are frequently used.

Of the twenty-one samples being studied consisted of 13 men (61.9%) and eight women (38.1%) with a mean of 21 years of age. The data analysis of the measurement using the independent t-test showed the thickness and the size of the prone position of the Achilles tendon, the 900 standard standing positions and dorsoflexion had resulted in the same value of P>0.05. This value means that there is no significant difference in the results. The examination results of the US Achilles tendon in both prone and standing position shows no description of anisotropy.

Due to no significant difference of thickness measurement results and area wideness of the Achilles tendon in a prone position and standing; moreover, in both standard and dorsoflexion, the standing position can then be used as an alternative technique to test the Achilles tendon ultrasound.

CONCLUSION

Modification technique of testing the Achilles tendon ultrasound in a standing position reveals no significant difference of the measurement results compared to a standard position, prone. Thus, the standing position becomes the alternative position of measurement technique on Achilles tendon US for the sonographer, doctor of radiology in improving patients' comfort without affecting the diagnostic value.

REFERENCES

- Beatrice S. F. Pang, Michael Ying. 2006. Sonographic Measurement of Achilles Tendons in Asymptomatic Subject: Variation With Age, Body Height, and Dominance of Ankle. *Journal Ultrasound Medicine*. 25, 1291–1296.
- Frank, H. Netter, MD. 2014. *Atlas of Human Anatomy*, Sixth Edition. Saunders Elsevier. Philadelphia. 503- 506.
- Bleakney, R.R., Lawrence M.W., et al., 2007. Imaging of the Achilles Tendon. *Springer*. 14, 25-38.
- Keneeth, S.Lee., 2012. Musculoskeletal Sonography of The Tendon. *Journal Ultrasound Medicine*. 31, 1879-1884.
- Hatzenbuehler, John. 2013. *Basic of Musculoskeletal Ultrasound*. Springer. New York. 70.
- Intziegianni. Konstantina, M. Cassel, K. Fro'hlich, T. Engel, F. Mayer. 2015. Measuring Achilles Tendon Length: A Simple and Reliable Method. *Sports Orthopedics and Traumatology*. 31, 260-266.
- Bradley, Mike., Paul O'Donnel. 2002. *Atlas of Musculoskeletal Ultrasound Anatomy*. Cambridge University Press. UK. 224-228.
- Syha, R., S.Grau, A.M. Nies, et al., 2014. Computer-based quantification of the Achilles tendon thickness in sequential B-mode ultrasound images: a study of feasibility and reliability. *Arch Orthop Trauma Surg*. 134, 1443–1449.
- Olszewski. Katarzyna, T.J.M. Dick, J.M.Wakeling. 2015. Achilles tendon moment arms: The importance of measuring at constant tendon load when using the tendon excursion method. *Journal of Biomechanics*. 48, 1206-1209.
- Oliveira. L. Fernandesde, C.C. Peixinho, G.A.Silva, L.L. Menegaldo . 2016. In vivo passive mechanical properties estimation of Achilles tendon using ultrasound. *Journal of Biomechanics*. 49, 507-513.
- Chimenti, R.L., A. Samuel F., et al., 2015. Ultrasound Strain Mapping of Achilles Tendon Compressive Strain Patterns During Dorsiflexion. *Journal of biomechanics*. 49, 39-44.
- Department of Musculoskeletal Radiology, University of Wisconsin School of Medicine and Public Health. 2012. *American Institute of Ultrasound In Medicine*. 0278-429.
- Palmer, P.E.S. 1995. *Manual of Diagnostic Ultrasound*. World Health Organization. Geneva. 3-15.
- Morrison, S.M., Taylor J.M., et al., 2015. Structural and Mechanical Properties of The Human Achilles Tendon: Sex and Strength Effects. *Journal of Biomechanics*. 48, 3530-3533.
- Bushong, Stewart C. 1999. *Diagnostic Ultrasound*. McGraw-Hill Companies. USA. 57-67.
- Tweedell, Andrew J., Eric D.R., et al., 2016. The Influence of Ultrasound Measurement Techniques On The Age- Related Differences In Achilles Tendon Size. *Journal Experimental Gerontology*. 76, 68-71.