

12-31-2018

## Is Simvastatin Associated with Oral Lichenoid Drug Reaction?

Kobkan Thongprasom

*Oral Medicine Department, Faculty of Dentistry, Chulalongkorn University, Bangkok 10330, Thailand,*  
kobkan.t@chula.ac.th

Follow this and additional works at: <https://scholarhub.ui.ac.id/jdi>

---

### Recommended Citation

Thongprasom, K. Is Simvastatin Associated with Oral Lichenoid Drug Reaction?. *J Dent Indones.* 2018;25(3): 175-177

This Literature Review is brought to you for free and open access by the Faculty of Dentistry at UI Scholars Hub. It has been accepted for inclusion in Journal of Dentistry Indonesia by an authorized editor of UI Scholars Hub.

## **LITERATURE REVIEW**

# **Is Simvastatin Associated with Oral Lichenoid Drug Reaction?**

**Kobkan Thongprasom**

*Oral Medicine Department, Faculty of Dentistry, Chulalongkorn University, Bangkok 10330, Thailand*  
Correspondence e-mail to: [kobkan.t@chula.ac.th](mailto:kobkan.t@chula.ac.th)

## **ABSTRACT**

Currently, various drugs have been found to induce many oral lesions. Some medications used to treat systemic diseases can affect the oral mucosa and induce lesions known as oral lichenoid drug reaction (OLDR). The diagnosis is made when the oral lesion erupted after the patient took a specific medication. However, diagnosis is challenging when a patient takes multiple medications and the onset of the eruption is unclear. OLDRs commonly cause severe pain in the oral cavity and affect the quality of life. Statins are widely used by patients with cardiovascular disease (CVD) to lower blood cholesterol levels, decreasing the risk of heart attack or stroke. This review will focus the side effects of a hypolipidemic drug group (statins) in the oral cavity. From previous experience, simvastatin may be related to severe oral ulcerations, dysplasia, and carcinoma in situ in the oral mucosa. Moreover, simvastatin combined with amlodipine can induce more severe oral lesions that are very difficult to treat. Therefore, the beneficial effect of these drugs and their side effects should be considered carefully, because simvastatin significantly affects oral and general health.

**Key words:** amlodipine, oral lichenoid, simvastatin

How to cite this article: Kobkan Thongprasom. Is simvastatin associated with oral lichenoid drug reaction? *J Dent Indones.* 2018;25(3):175-177

## **INTRODUCTION**

The use of medications is increasing due to many patients with systemic diseases. Adverse reactions to medications are common and have a variety of clinical presentations in the oral cavity, the most common being xerostomia, lichenoid reactions, ulcers, bullous disorders, pigmentation, fibrovascular hyperplasia, white lesions, dysesthesia, osteonecrosis, infection, angioedema, and malignancy.<sup>1</sup>

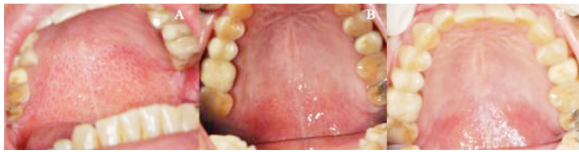
### **Simvastatin**

Hypolipidemic drugs, such as the statins, are widely used medications that are beneficial for patients with cardiovascular disease (CVD), but are less well established for primary prevention in asymptomatic patients.<sup>2</sup> The statins are a group of drugs that successfully lower blood cholesterol levels, decreasing the risk of heart attack or stroke. In recent years, statins, which are made from the fungus *Aspergillus terreus*, also have been reported to have other biological activities and numerous potential therapeutic uses.<sup>3</sup> Simvastatin is a lipid-lowering medication that is a hydroxymethyl-glutaryl-coenzyme A (HMG-CoA) reductase inhibitor.<sup>4</sup>

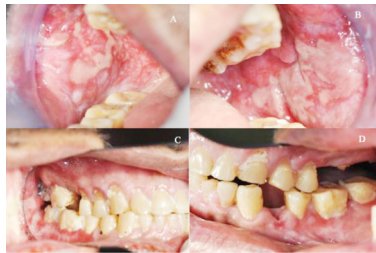### **Simvastatin and oral lichenoid drug reaction**

Roger et al.<sup>5</sup> first reported the side effects of simvastatin in 1994, describing that it induced lichenoid drug eruption on the skin and oral mucosa. The diagnosis of oral lichenoid drug reaction (OLDR) is sometimes very difficult when a patient takes multiple medications. However, history taking regarding the duration of medications taken and that the oral lesion erupted after using a specific drug is helpful in the diagnosis. Moreover, Naranjo et al.<sup>6</sup> designed a questionnaire to determine the likelihood of whether an adverse drug reaction has occurred. This questionnaire is useful during history taking from patients suspected to have OLDR.

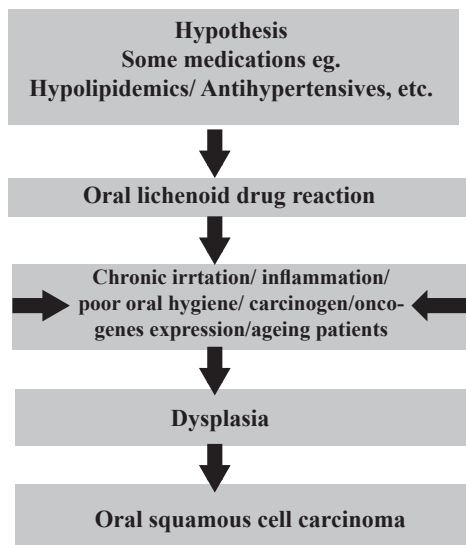
Severe OLDR can cause pain in the oral cavity and definitely affects quality of life and general health. Our experience in the Oral Medicine Clinic at the Faculty of Dentistry, Chulalongkorn University is the combination of simvastatin and amlodipine can induce more severe oral ulceration and OLDR. After stopping simvastatin, the severe oral lesions gradually resolve (Figure 1A–C). Moreover, when simvastatin is used together with many medications, the severe oral lesions are very difficult to treat and manage (Figure 2A–D). Therefore,



**Figure 1.** (A) Reticular and erythematous lesions on the palate in a 56-year-old male erupted after taking simvastatin and amlodipine for 7–8 months before treatment. (B) Improvement shown after stopping simvastatin and treating the lesions with triamcinolone acetonide 0.1% mouthwash for 3 weeks. (C) The palatal lesion resolved 7 months after treatment.



**Figure 2.** (A–D) Severe oral lichenoid drug reaction in a 62-year-old patient with a history of hypertension, stroke, dyslipidemia, and epilepsy who was taking amlodipine, simvastatin, acetylsalicylic acid, and clopidogrel. Poor oral hygiene and generalized severe ulceration, white striae, and erosion with a pseudomembranous cover can be seen.



**Figure 3.** A hypothesis on the relationship between medications, OLDR, chronic irritation, inflammation, poor oral hygiene, carcinogens, oncogene expression, and aging patients who may suffer dysplasia and squamous cell carcinoma.

simvastatin can be withdrawn when the patient’s cholesterol level is not high or is in the borderline range. The result of discontinuing simvastatin that induced erosive lichenoid lesions on the lower labial mucosa were included in the textbook *Oral and Maxillofacial Pathology*.<sup>7</sup> Interestingly, a previous study showed that

hypolipidemic drugs, such as the statins, were the most commonly used medication in eight of nine elderly patients (88.9%) with red and white lesions that were serum ANA–positive.<sup>8</sup>

Because of their potential for OLDR development, lists of medications that can induce OLDR should be referred to oral medicine specialists and physicians for consideration when managing a suspected OLDR lesion.<sup>9</sup> Withdrawal or replacement of the suspected drug with other medications is recommended. In fact, when a patient is using one medication only, it is not difficult to replace it with another and the oral lesion should resolve completely.<sup>10</sup> Managing a patient with OLDR is challenging and requires cooperation from the physician to understand the medications that caused the oral lesions. Cooperation between oral medicine specialists and physicians has been useful in managing these complicated cases. In severe cases, symptomatic treatment and determining the cause of the lesions are helpful in improving quality of life and general health. Antihypertensive drugs, such as amlodipine, a long-acting calcium channel blocker, also are widely used. However, the interaction between simvastatin and amlodipine is unresolved. Clinical trials have shown that simultaneous administration of simvastatin and amlodipine can increase simvastatin bioavailability.<sup>11</sup> With increasing use of HMG-CoA reductase inhibitors, the association between OLDR and these drugs should be considered carefully. Interestingly, a previous report suggested that, apart from their beneficial effect, statins might be implicated in the development of oral lichenoid lesions, moderate dysplasia, and carcinoma in situ of the oral mucosa in an aging patient.<sup>12</sup> Longstanding OLDR lesions caused by various factors may possibly transform to oral malignancy in the future (Figure 3).<sup>13</sup>

To our knowledge, few reports exist of simvastatin inducing severe oral ulceration or OLDR. Furthermore, red and/or white lesions in the oral mucosa must be considered and correctly diagnosed, particularly in older patients. Early diagnosis and proper management can prevent unfavorable outcomes of those patients. Although statins currently are the preferred pharmaceutical intervention for reducing the probability of CVD, statin-associated autoimmune myopathy exists as a rare side effect. Recently, the very interesting case of a 69-year-old man with early onset diabetes mellitus precipitated by a small dose of simvastatin highlighted the potential role of statins as triggers of an immune system disease, statin-induced dermatomyositis. This disease is rare and extremely unusual adverse event associated with simvastatin use and very few fatal cases have been reported. Nevertheless, rare cases can take a lethal course.<sup>14</sup> Further investigation into the mechanism and side effects of these drugs will be useful for patients because these drugs are widely used in the general population.

## CONCLUSION

Various medications have side effects that range from mild to severe, including eruption of severe oral lesions. These lesions, such as generalized oral ulcerations, can cause pain and suffering in the oral cavity. Simvastatin commonly is taken by patients with hypercholesterolemia. However, for those with borderline cholesterol levels, an alternative treatment should be recommended, such as weight control or avoiding high-fat food consumption to prevent the untoward effects that can occur when taking this drug. Simvastatin alone or in combination with amlodipine or other drugs should be investigated further for the possible interaction of side effects to the oral mucosa. Severe and painful oral lesions affect oral hygiene and quality of life in these patients. Moreover, oral mucosal changes are an indicator of oral and general health. Therefore, oral medicine specialists, physicians, and dentists can have important roles, prevent the side effects of these drugs in the oral cavity, and possibly save the patient's life. Further studies on these drugs may be important for oral and global health.

## ACKNOWLEDGMENTS

This review manuscript is a part of an oral presentation entitled "Oral Medicine perspective and global health" for the "3<sup>rd</sup> International Conference on Global Health (ICGH) that was held in conjunction with the 3<sup>rd</sup> International Workshop on Dental Research (IWDR) and the 1<sup>st</sup> International Seminar on Clinical and Research in Dentistry (ISCaRD)," Bali, Indonesia during 14–16 September, 2018. I thank the Research Unit in Oral Diseases, Chulalongkorn University for long term support. I thank the Oral Medicine staff for their kind assistance. Our patients are also thanked for their cooperation. I also thank Dr. Kevin Tompkins for reviewing and editing this manuscript.

## REFERENCES

1. Yuan A, Woo SB. Adverse drug events in the oral cavity. *Oral Surg Oral Med Oral Pathol Oral Radiol.* 2015;119 (1):35-47.
2. Silverman MG, Ference BA, Im K, Wiviott SD, Giugliano RP, Grundy SM, et al. Association between lowering LDL-C and cardiovascular risk reduction among different therapeutic interventions: a systematic review and meta-analysis. *JAMA.* 2016;316:1289-97.
3. Barrios-González J, Miranda RU. Biotechnological production and applications of statins. *Appl Microbiol Biotechnol.* 2010;85(4):869-83.
4. Todd PA, Goa K. Simvastatin: a review of its pharmacological properties and therapeutic potential in hypercholesterolaemia. *Drugs.* 1990;40(4):583-607.
5. Roger D, Rolle F, Labrousse F, Brosset A, Bonnetblanc JM. Simvastatin-induced lichenoid drug eruption. *Clin Exp Dermatol.* 1994;19(1):88-9.
6. Naranjo CA, Busto U, Sellers EM, Sandor P, Ruiz I, Roberts EA, et al. A method for estimating the probability of adverse drug reactions. *Clin Pharmacol Ther.* 1981;30(2):239-45.
7. Neville BW, Damm DD, Allen CM, Chi AC. *Oral and Maxillofacial Pathology.* 4<sup>th</sup> ed. St. Louis, Mo: Saunders Elsevier; 2016. p319.
8. Prucktrakul C, Youngnak-Piboonratanakit P, Prueksrisakul T, Kanjanabuch P, Thongprasom K. Oral lichenoid lesions and serum antinuclear antibodies in Thai patients. *J Oral Pathol Med.* 2015;44(6):468-74.
9. Wiriyakijja P, Nakpipat P, Thongprasom K. Challenge management of Oral Lichenoid Drug Reaction. *Adv Dent Oral Health.* 2017;5(1):555656.
10. Bagan VJ, Thongprasom K, Scully C. Adverse oral reactions associated with the COX-2 inhibitor Rofecoxib. *Oral Dis.* 2004;10(6):401-3.
11. Schröder J, Goltz L, Knoth H. Medication management: Simvastatin and Amlodipin - a clinically relevant drug-interaction? *Dtsch Med Wochenschr.* 2016;141(21):1575-7.
12. Phattaratatip E, Dhanuthai K, Thongprasom K. Carcinoma *In situ* arising in the Oral Lichenoid Lesion - An Unusual Case Report. *J Med Surg Pathol.* 2016;1:133.
13. Peng Q, Zhang J, Ye X, Zhou G. Tumor-like microenvironment in oral lichen planus: evidence of malignant transformation? *Expert Rev Clin Immunol.* 2017;13(6):635-43.
14. Chemello RML, Benvegnú AM, Dallazem LND, Chemello D. Aggressive and fatal statin-induced dermatomyositis: a case report. *Oxf Med Case Reports.* 2017;2017(12):omx063.

(Received October 27, 2018; Accepted November 10, 2018)