

12-31-2020

## Prevalence of nail changes in patients infected with HIV - A cross sectional study

Seethalakshmi Ganga Vellaisamy

*Department of Skin & Sexually Transmitted Diseases, Vinayaka Mission's Kirupananda Variyar Medical College & Hospital Vinayaka Mission's Research Foundation Salem, Tamil Nadu 636308, India*

Priya Jeyaraman

*Department of Skin & Sexually Transmitted Diseases, Vinayaka Mission's Kirupananda Variyar Medical College & Hospital Vinayaka Mission's Research Foundation Salem, Tamil Nadu 636308, India*

Kannan Gopalan

*Department of Skin & Sexually Transmitted Diseases, Vinayaka Mission's Kirupananda Variyar Medical College & Hospital Vinayaka Mission's Research Foundation Salem, Tamil Nadu 636308, India*

Follow this and additional works at: <https://scholarhub.ui.ac.id/jdvi>



Part of the [Dermatology Commons](#), [Integumentary System Commons](#), and the [Skin and Connective Tissue Diseases Commons](#)

---

### Recommended Citation

Vellaisamy, Seethalakshmi Ganga; Jeyaraman, Priya; and Gopalan, Kannan (2020) "Prevalence of nail changes in patients infected with HIV - A cross sectional study," *Journal of General - Procedural Dermatology & Venereology Indonesia*: Vol. 5: No. 1, Article 1.

DOI: 10.19100/jdvi.v5i1.228

Available at: <https://scholarhub.ui.ac.id/jdvi/vol5/iss1/1>

This Article is brought to you for free and open access by UI Scholars Hub. It has been accepted for inclusion in Journal of General - Procedural Dermatology & Venereology Indonesia by an authorized editor of UI Scholars Hub.

## Prevalence of nail changes in patients infected with HIV - A cross sectional study

Seethalakshmi Ganga Vellaisamy, Priya Jeyaraman, Kannan Gopalan

Department of Skin & Sexually Transmitted Diseases,  
Vinayaka Mission's Kirupananda Variyar Medical College & Hospital  
Vinayaka Mission's Research Foundation  
Salem, Tamil Nadu 636308, India

Email: [dr.seethalakshmiyadav@gmail.com](mailto:dr.seethalakshmiyadav@gmail.com)

### Abstract

**Background:** The spectrum of nail changes is wide, and their frequency is higher among patients with HIV. These changes magnify the range and multiplicity of AIDS manifestations. Their systematic examination is noninvasive, simple method of possible diagnostic value. This study was conducted to study the variety of nail changes in HIV-infected individuals and to correlate those nail changes with CD4+ count.

**Materials and Methods:** This is a cross-sectional observational study, conducted on patients who attended the skin and sexually transmitted diseases outpatient department in a tertiary care hospital between March 2018 and April 2019. One hundred seventy-six HIV-positive patients were included in the study. Dermatological examination was performed, and surface changes, color variations, thickness, and curvature of nail plates were recorded. Data were coded and analyzed.

**Results:** The prevalence of nail changes in our study was 60.8%. Most patients were 34–41 years old (38.1%) with a slight female preponderance. Absent lunula/ anolunula (33.5%), diffuse pigmentation of nails (29.54%), and nail dystrophy (18.2%) were the top three nail changes, followed by longitudinal melanonychia (13.06%), flat nails (4%), onychomycosis (3.4%), and pterygium (2.8%). Most patients with abnormal nails had a CD4+ count of more than 500 cells/mm<sup>3</sup> (30.68%). The chi-square test was done to find the strength of association between abnormal nail changes and CD4+ count. The p-value was 0.575, which was not statistically significant.

**Conclusion:** This study infers that systematic nail examination of HIV-infected patients is necessary, but the relation to the level of immunosuppression requires further large-scale, multicenter studies.

**Key words:** CD4+ count, HIV/AIDS, nail changes, anolunula

### Introduction

HIV infection is a major health problem in all age groups and is associated with significant morbidity and mortality. Dermatological disorders are common in all stages of HIV infection. Many mucocutaneous changes or specific skin diseases are associated with HIV infection.<sup>1</sup> The nail unit behaves as a mirror and reflects specific changes that are markers for various systemic disorders. The spectrum of nail changes is wide, and the frequency is higher among patients with HIV. Most

of the changes are linked to the level of immunosuppression. Systematic research and recording are a noninvasive method of a possible diagnostic value. A few studies only have given attention to nail changes that can occur in association with HIV infection.<sup>2</sup>

This study introduced nail changes in HIV-infected individuals as a marker of the immune status for a grassroots-level setup in low-income countries like India. Usage of nail changes as markers of systemic disorders has increased since trained healthcare personnel can detect these changes in

a standardized, objective fashion without any expensive diagnostic methodologies. This study aims to explain the various types of nail changes in HIV-positive individuals and correlate nail manifestations with CD4+ count.

## Materials and Methods

This was a cross-sectional observational study after obtaining approval from the ethical committee of our institution. The study population included all patients with HIV age more than 18 years, irrespective of their antiretroviral treatment (ART) status, who attended The Skin and Sexually Transmitted Diseases Outpatient Department Salem, India during the study period of March 2018 to April 2019. Patients with HIV had other dermatological diseases like psoriasis, eczema, or erythroderma were excluded from the study. There was no control group in the study, patients with nails changes without HIV were not included in the study.

A written informed consent for the clinical examination of the patients included in the study was obtained. Demographic features, high-risk behavior, and mode of contracting HIV infection and duration were collected from all patients using a predesigned questionnaire. The recent CD4+ count of each patient was taken from the patient's medical records. Dermatological examination was performed on all participants; surface changes, color variations, thickness, and curvature of nail plates were recorded. The periungual area was also examined. The diagnosis was made on the basis of a detailed history and clinical examination. Digital photographs were taken after obtaining the consent.

Abnormal nail changes were correlated with CD4+ count and the stage of disease (WHO staging) in the study population. Data analysis was done using SPSS version 16 (SPSS, Inc., Chicago, IL, USA). The chi-square test was done to find the strength of association between abnormal nail changes and CD4+ count. The level of significance was estimated with 95% confidence interval and p-value < 0.05.

## Results

One hundred seventy-six HIV-positive patients who attended the skin and STDs outpatient department during the study period of March 2018 to April 2019 were included in the study. Of the 176 patients, 107 (60.8%) had a nail abnormality, whereas 69 patients (39.2%) had normal nails.

Most of the patients were 34–41 years old (38.1%). 27.8% of the patients were 42–49 years old and 20.5% were in the age group of more than 49 years, whereas 11.4% were 26–33 years old. Only 2.3% of the patients were 18–25 years old. The mean age of our study population was found to be 36.17 years. Females (57.4%) outnumbered males (42.6%) in our study, and the male-to-female ratio was 1:1.34.

Regarding the occupations of the patients, 72.2% were farmers, 20.5% were housewives, 6.2% were unemployed, 0.6% had a clerical job, and 0.6% were professionals. Substance abuse disorder was present in 21.6% of the study population. Of the 176 individuals, heterosexual transmission was seen in 175 individuals (99.4%), and vertical transmission was seen in only one individual (0.6%). Most of the patients (96.6%) were on ART treatment, either zidovudine, lamivudine, and efavirenz regimen or tenofovir, lamivudine, and efavirenz regimen. Regarding the associated opportunistic infections in the patients, about 18.2% had pulmonary tuberculosis, 3.4% had oral candidiasis, 1.1% had chronic diarrhea, and 0.6% had herpes zoster. About 10.8% of the HIV-positive patients had a CD4+ count of < 200 cells/mm<sup>3</sup>, 38.6% had a CD4+ count between 200 and 500 cells/mm<sup>3</sup>, and 50.6% had a CD4+ count of > 500 cells/mm<sup>3</sup>.

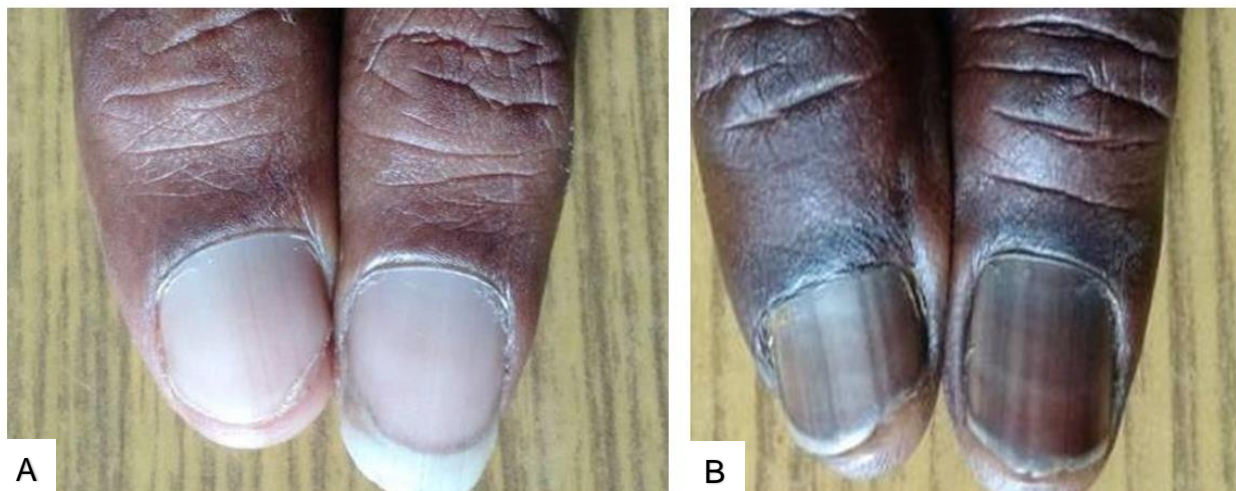
Almost 12 types of nail changes were identified in the study population (Table 1). Absent lunula/anolunula (33.5%) (Figure 1A), diffuse pigmentation of the nails (29.54%) (Figure 1B), and nail dystrophy (18.2%) occupied the top three nail changes in our study, followed by longitudinal melanonychia (13.06%) (Figure 2A), flat nails (4%) (Figure 2B), onychomycosis (3.4%) (Figure 3A and 3B), and pterygium (2.8%) (Figure 4). Diffuse pigmentation of nails was seen in 52 (29.54%) patients. Of these 52 patients, 40 patients (76.92%)

were on zidovudine-based ART regimen. Longitudinal melanonychia was seen in 23 (13.06%) patients. Of these 23 patients, 18 (78.3%) patients were on zidovudine-based ART regimen.

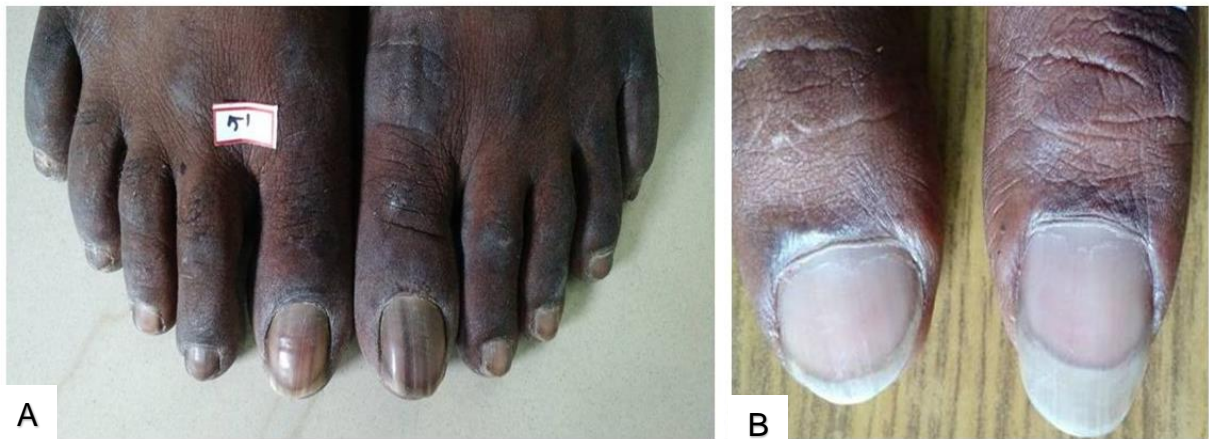In our study, 76 (43.18%) patients who had abnormal nails belonged to WHO stage I, 6 (3.4%) patients belonged to WHO stage II, and 25 (14.2%) patients belonged to WHO stage III.

**Table 1.** Distribution of Nail Changes According to the Category in the Study Population

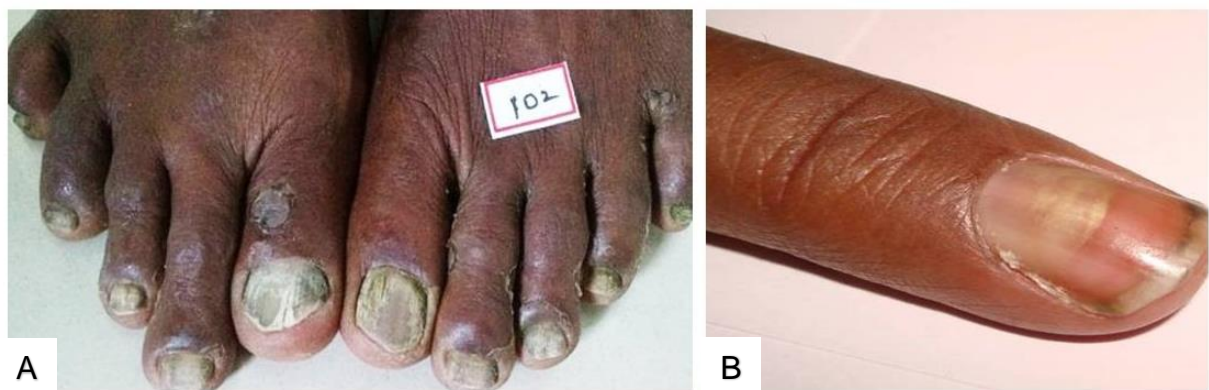
Nail change	Frequency	Percent
Anolunula	117	66.5
Diffuse pigmentation	52	29.54
Nail dystrophy	32	18.2
Longitudinal melanonychia	23	13.06
Flat nails	7	4
Onychomycosis	6	3.4
Pterygium	5	2.8
Clubbing	4	2.3
Longitudinal ridging	1	0.6
Transverse lines	1	0.6
Onychoschizia	1	0.6
Beau's lines	1	0.6



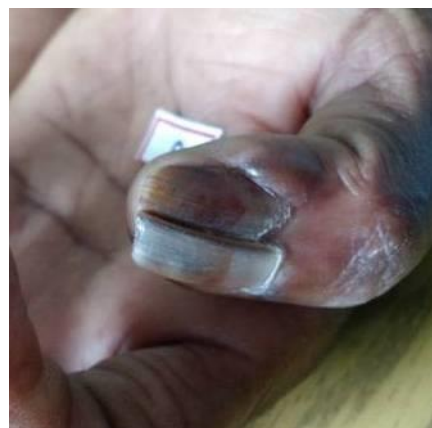**Figure 1.** Clinical presentation of nail changes. A. Anolunula. B. Diffuse pigmentation of nails



**Figure 2.** Clinical presentation of nail changes in HIV patients. A. Longitudinal melanonychia  
B. Flat nails



**Figure 3.** Clinical presentation of nail changes in HIV patients. A. Total dystrophic onychomycosis.  
B. Proximal subungual onychomycosis



**Figure 4.** Clinical presentation of pterygium in HIV patients

In our study, of the patients with abnormal nails, 10 (5.68%) were in the group of less than one year after diagnosis, 29 patients (16.47%) were in the group of one to three years after diagnosis, 20 patients (11.36%) were in the group of three to five years after diagnosis, and 48 patients (27.27%) were in the group of more than five years after diagnosis. Most of the subjects were in the group of more than five years after diagnosis. The chi-square test was done to find the association between abnormal nail changes and CD4+ count (Table 2). The p-value was found to be 0.575, which was not statistically significant.

## Discussion

Since the first report of HIV infection in 1981, the importance and frequency of the associated nail manifestations have not been much recognized. It is tentatively accepted by clinicians that certain nail manifestations of HIV disease are of great value in representing that they may be the first sign of the disease (e.g., proximal subungual white

onychomycosis), and they have been shown to be highly predictive markers of immunodeficiency and progression of the disease, but the specificity of such nail changes were never assessed.

The prevalence of nail changes was found to be 60.8% among our study subjects, whereas Valenzano et al. showed a low prevalence (32.5%) of nail changes in his study.<sup>2</sup> However, Cribier et al. showed a high prevalence of nail changes (67.7%) in his study.<sup>3</sup> These discrepancies in the prevalence of HIV-associated nail changes may be explained by many determinants like race, socioeconomic status, condition of the nails before infection, and examiner's clinical acumen in diagnosing nail changes.

The most common nail changes in our study population were anolunula, followed by diffuse pigmentation, and nail dystrophy, whereas Cribier et al.<sup>3</sup> found that onychomycosis was the most common manifestation (Table 3). Most of the nail changes (27.27%) were seen in patients who had a much earlier diagnosis of HIV.

**Table 2.** Correlation between CD4+ Count and Nail Changes

CD4+ count	Normal nails n (%)	Abnormal nails n (%)	Total n (%)
0–200	6 (3.40)	13 (7.38)	19 (10.79)
200–500	28 (15.90)	40 (22.72)	68 (38.63)
>500	35 (19.88)	54 (30.68)	89 (50.56)
Total	69 (39.20)	107 (60.8)	176 (100)

**Table 3.** Overall Prevalence of Common Nail Changes in This Study Population and Comparable Study

No.	Researcher, year	Study population	Sample size	Most common nail changes
1	This study, 2018	India	176 patients	1. Anolunula (66.5%) 2. Diffuse pigmentation (29.54%) 3. Nail dystrophy (18.2%)
2	Cribier et al., 1998 <sup>3</sup>	France	155 patients	1. Onychomycosis (30.3%) 2. Melanonychia (14.8%) 3. Longitudinal ridging (11.6%)

The prevalence of anolunula in our study is 66.5%, while it was 45.83% in Pratik et al. study.<sup>4</sup> In our study, lunula was absent in patients whose CD4+ count was more than 500 cells/mm<sup>2</sup> (33.52%), therefore we cannot confirm these findings to the level of immunosuppression. A comparative study on patients having other long-standing ailments could help differentiate whether this change is specifically associated with HIV infection. Alterations in vascular or lymphatic channels may be the reason behind the presence of anolunula in HIV-infected individuals as it is difficult to pinpoint the exact cause of anolunula.

Systemic diseases may affect the proximal nail fold vessels, which is a well-documented entity. Dysfunctional endothelium and injury of endothelial cells have been described in HIV infection.<sup>5,6</sup> HIV infection per se has been a reason for premature atherosclerosis seen in young adults, despite the absence of provoking factors or treatment with

protease inhibitors.<sup>7</sup> HIV-infected monocyte-macrophage interaction, possibly through altered adhesion of leukocytes or arteritis stimulates atherogenesis.<sup>8</sup> Briefly, endothelial injury affects nail growth in HIV-infected patients and subsequently results in anolunula. This can only be proven by performing a biopsy and observing sequential histopathological changes occurring in nails in HIV-positive patient.

In regards to onychomycosis in patients with HIV several characteristics are identified, which are multiple nail involvement; the presence of both common and rare species; and drug resistance. In Canadian and Brazilian studies, the prevalence of onychomycosis was 24% and 20% of the study population, respectively.<sup>9</sup> Similarly, Cribier et al. reported a prevalence of 30.32% in France.<sup>3</sup> Our study reported a prevalence of 3.4%, which is less compared with the aforementioned studies (Table 4).

**Table 4.** Overall Prevalence of Onychomycosis in This Study Population and Comparable Studies

No.	Researcher Year	Place Sample size	Total Prevalence	PSO	DLSO	TDO	WSO
1	This study 2018	India 176 patients	3.4%	83.33%	0%	16.6%	0%
2	Cribier et al. 1998 <sup>3</sup>	France 155 patients	30.3%	-	-	-	-
3	Gupta et al. 2000 <sup>9</sup>	Canada 500 patients	23.2%	7.08%	78.75%	0%	14.17%
4	Herranz et al. 1997 <sup>15</sup>	Spain 21 patients	-	19.04%	47.61%	28.57%	4.76%
5	Amar et al. 2007 <sup>14</sup>	India 250 patients	-	8.33%	35%	55%	1.66%
6	Kore et al. 2013 <sup>16</sup>	India 352 patients	6.3%	1.2%	-	-	-
7	Vijaya et al. 2017 <sup>17</sup>	India 100 patients	5%	-	-	-	-

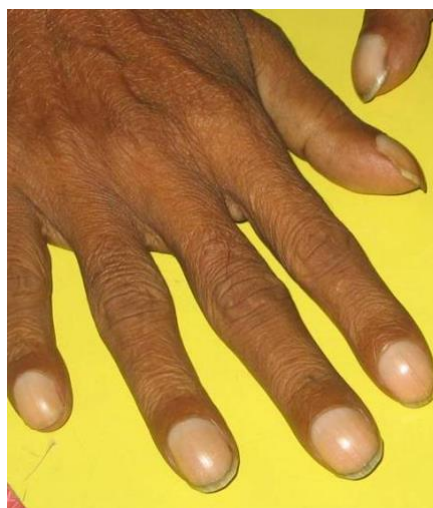
PSO: proximal subungual onychomycosis, DLSO: distal and lateral superficial onychomycosis, TDO: total dystrophic onychomycosis, WSO: white superficial onychomycosis

The prevalence of onychomycosis in HIV infection varies between 15% and 40% in various studies, which was reported in the literature.<sup>10-13</sup> The cause for the low prevalence of onychomycosis in our study was that we did not do any nail clipping. In our study, finger nails were mainly affected more than toe nails, whereas, in Cribier et al.'s study<sup>3</sup> and Amar et al. study,<sup>14</sup> toe nails were frequently affected.

Proximal subungual onychomycosis (PSO) was the most common type found in our study (Figure 3B). Whereas, Gupta et al.'s and Herranz et al.'s found distal and lateral superficial onychomycosis (DLSO) was the most common type.<sup>9,15</sup> In Amar et al.'s study, total dystrophic onychomycosis (TDO) was the most common type observed.<sup>14</sup> In our study, onychomycosis was more commonly seen in patients with a CD4+ count in the range of 200–500 cells/mm<sup>3</sup> (50%) and more than 500 cells/mm<sup>3</sup> (50%). Even though onychomycosis is not a life-threatening manifestation in HIV-positive patients it can be a source of morbidity. Since patients who have onychomycosis find it difficult to hide it from social life, it leads to a psychological burden for HIV-infected individuals.

The overall prevalence of pigmentary changes in our study was 40.9%, while it was 5.4% in Sachin et al.'s study.<sup>16</sup> Though we are attributing zidovudine as the cause for longitudinal melanonychia in 78.3% of the patients and diffuse pigmentation in 76.92% of the patients, these pigmentary changes vary considerably among different races. Longitudinal melanonychia was more commonly (6.25%) seen in patients having a CD4+ count in the range of 200–500 cells/mm<sup>3</sup>, and diffuse pigmentation of nails (15.90%) was most commonly seen in HIV-positive patients who had a CD4+ count of more than 500 cells/mm<sup>3</sup>; this is because patients who receive ART will have a robust immune response.<sup>17</sup>

The prevalence of clubbing in our study was 2.3% (Figure 5), while it was 5.8% in Cribier et al.'s study.<sup>3</sup> We could not attribute the cause to any associated systemic disorders like suppurative lung disease or cardiac diseases in our study population. Transverse lines across the nail have occasionally been seen in HIV-infected patients and it is either attributed to serum zinc depletion or is a consequence of episodes of severe illness.<sup>13</sup> In our study, it was seen in 0.6% of the patients, whereas in Cribier et al.'s study it was in 7.7% of the patients.<sup>3</sup>



**Figure 5.** Clinical presentation of clubbing fingers in HIV patients



It was hypothesized in Cribier et al. study<sup>3</sup> that the altered color, brittle nails, and onychoschizia reflect the various disorders seen in patients with HIV, but it was unclear whether they are present as a consequence of metabolic changes, repeated opportunistic infections, or nutritional deficiencies. We noticed onychoschizia in 0.6% of the study population, while in Cribier et al.'s study,<sup>3</sup> it was seen in 7.1% of the patients. We did not observe any case of periungual erythema and splinter hemorrhage in our study.

In our study, abnormal nail changes were mostly observed in patients who presented with a CD4+ count of more than 500 cells/mm<sup>3</sup> (30.68%), but we could not find any statistical significance. In some studies, nail changes have been shown to be markers of HIV infection (e.g., proximal subungual white onychomycosis), but the specificity of nail changes to the level of immunosuppression was never assessed. Nevertheless, we cannot confirm that the nail findings that we observed in our study population could be due to HIV infection. A comparison with a control group with other chronic illnesses could help us identify which nail symptoms are more specifically associated with HIV.

## Conclusion

In this cross-sectional study of 176 HIV-infected patients, we found a 60.8% prevalence of nail changes, which consist of anolunula (33.5%), diffuse pigmentation of nails (29.54%), and nail dystrophy (18.2%) were the top three nail changes in our study. Limitations of the study are this was observational with no control group and potassium hydroxide mount was not done for onychomycosis because lacking of resources.

As more patients receive zidovudine, it is important to alert patients about nail pigmentation. Even though this pigmentation is reversible and harmless, the psychological aspects of this side effect may impair the compliance to therapy, thereby leading to poor adherence. This may also lead to unwanted investigations and treatment for a misdiagnosis, such as cyanosis and melanoma. In conclusion, systematic nail examination of HIV-infected patients is necessary and valuable for treating physicians, but the relation to the level of

immunosuppression requires further large-scale, multicenter studies.

## References

1. Dover JS, Johnson RA. Cutaneous manifestations of human immunodeficiency virus infection syndrome. *Arch Dermatol.* 1992;127:1383-91.
2. Valenzano L, Giacalone B, et al. Compromissione ungueale in corso di AIDS [in Italian]. *Giorn Ital Dermatol.* 1988;123:527-8.
3. Cribier B, Mena ML, Rey D, et al. Nail changes in patients infected with human immunodeficiency virus. A prospective controlled study. *Arch Dermatol.* 1998;134:1216-20.
4. Gahalaut P, Mishra N, Chauhan S, Ali MM, Rastogi MK, Thakur R. Anolunula in fingernails among patients infected with HIV. *ISRN Dermatology.* 2014; 2014:271230.
5. Chi D, Henry J, Kelley J, Thorpe R, Smith JK, Krishnaswamy G. The effects of HIV infection on endothelial function. *Endothelium* 2000; 7(4):223-42.
6. Barbaro G, Klatt EC. HIV infection and the cardiovascular system. *AIDS Rev* 2002;4(2):93-103.
7. Prendergast BD. HIV and cardiovascular medicine. *Heart* 2003;89(7):793-800.
8. Barbaro G. HIV infection, highly active antiretroviral therapy and the cardiovascular system. *Cardiovasc Res.* 2003;60(1):87-95.
9. Gupta AK, Taborda P, Taborda V, et al. Epidemiology and prevalence of onychomycosis in HIV-positive individuals. *Int J Dermatol.* 2000;39:746-53.
10. Goodman DS, Teplitz ED, Wishner A, Klein RS, Burk PG, Hershenbaum E. Prevalence of cutaneous disease in patients with acquired immunodeficiency syndrome (AIDS) or AIDS related complex. *J Am Acad Dermatol.* 1987;17:210-20.
11. Matis WL, Triana A, Shapiro R, Eldred L, Polk BF, Hood AF. Dermatologic findings associated with human immunodeficiency virus infection. *J Am Acad Dermatol.* 1987;17:746-51.
12. Kaplan MH, Sadick N, McNutt NS, Meltzer M, Sarngadharan MG, Pahwa S. Dermatologic findings and manifestations of acquired immunodeficiency syndrome (AIDS). *J Am Acad Dermatol.* 1987;16:485-506.

13. Prose NS, Abson KG, Scher RK. Disorders of the nails and hair associated with human immunodeficiency virus infection. *Int J Dermatol.* 1992;31:453-57.
14. Surjushe A, Kamath R, Oberai C, et al. A clinical and mycological study of onychomycosis in HIV infection. *Indian J Dermatol Venereol Leprol.* 2007;73:397-401.
15. Herranz P, Garcia J, De Lucas R, et al. Toenail onychomycosis in patients with acquired immune deficiency syndrome: treatment with terbinafine. *Br J Dermatol.* 1997;137:577-80.
16. Kore SD, Kanwar AJ, Vinay K, Wanchu A. Pattern of mucocutaneous manifestations in human immunodeficiency virus-positive patients in North India. *Indian J Sex Transm Dis.* 2013;34:19-24.
17. Vijaya AK, Sreenivasulu RN, Deepthi M, Penchalaiah K. Study of skin, hair and nail changes among HIV patients and their correlation with CD4 count. *Annals of International Medical and Dental Research* 2017;3(3):DT01-4.