

4-30-2019

## Influence of Pretreatment Root Development Stage on success of Apexification: Forensic Dental Evaluation

Myroslav Goncharuk-Khomyn

*Uzhhorod National University, Uzhhorod, Ukraine, myroslav.goncharuk-khomyn@uzhnu.edu.ua*

Follow this and additional works at: <https://scholarhub.ui.ac.id/jdi>

---

### Recommended Citation

Goncharuk-Khomyn, M. Influence of Pretreatment Root Development Stage on success of Apexification: Forensic Dental Evaluation. J Dent Indones. 2019;26(1): 37-43

This Article is brought to you for free and open access by the Faculty of Dentistry at UI Scholars Hub. It has been accepted for inclusion in Journal of Dentistry Indonesia by an authorized editor of UI Scholars Hub.

## ORIGINAL ARTICLE

# Influence of Pretreatment Root Development Stage on success of Apexification: Forensic Dental Evaluation

Myroslav Goncharuk-Khomyn

*Uzhhorod National University, Uzhhorod, Ukraine*

*Correspondence e-mail to: myroslav.goncharuk-khomyn@uzhnu.edu.ua*

## ABSTRACT

Clinicians have previously reported effective outcomes of apexification in cases of complicated caries or trauma; however, there is still not enough evidence of how root development stage before treatment influences the success of this procedure. **Objectives:** The study was performed to evaluate the influence of pretreatment root development stage on the success of apexification, with the use of a modified forensic technique for estimating odontologic age. **Methods:** Apexification of maxillary and mandibular permanent incisors, first molars, and premolars was provided to 43 pediatric patients with symptoms of irreversible pulp changes or signs of chronic apical periodontitis. Success of apexification was evaluated with the use of a modification of Demirjian et al.'s age estimation technique; root development stages were documented radiologically before and 12 months after treatment. **Results:** There was a close covariance between pretreatment tooth development stages F and G and the possibility of achieving stage H after apexification ( $r_s = 0.87$  and  $0.91$ , respectively;  $p < 0.05$ ) with an average follow-up period of  $11.6 \pm 0.7$  months. **Conclusion:** Pretreatment tooth development at stages F to H, as originally proposed by Demirjian et al., was found to significantly influence the prognosis for achieving successful apexification outcome.

**Key words:** root apexification, forensic dentistry, age estimation, odontologic age

How to cite this article: Myroslav Goncharuk-Khomyn. Influence of pretreatment root development stage on success of apexification: forensic dental evaluation. *J Dent Indones.* 2019;26(1): 37-43

## INTRODUCTION

Quality evaluation of dental interventions remains one of the most discussed topics among dental professionals. Although standards of dental treatment continue to improve, the criteria used in the quality assurance tests of clinical conditions in different situations are arguably scant.<sup>1-3</sup> On the other hand, improvement in dental care quality and reduction of the costs for most dental procedures are essential aspects of medical reform in many European countries.<sup>1,3</sup> Various scientific publications and analyses have been devoted to the question of establishing specific methods of and approaches to the assessment of dental care quality, which reflects the cross-disciplinary character and complexity of this issue.<sup>4-10</sup> According to summarized results of previously published surveys, quality of dental treatment can be high only if a positive functional prognosis after treatment can be guaranteed with specific statistical evidence.

During the endodontic interventions in cases of complicated caries or trauma of a tooth with an

incompletely formed root, clinicians may perform an apexification procedure.<sup>11-13</sup> Although authors have previously reported effective outcomes of apexification, there is still not enough evidence of how root development stage before treatment influences the success of such a procedure. Moreover, objective criteria are needed to evaluate this influence. In most previously published articles on this topic, authors have predicted the outcome of such treatment by considering only clinical symptoms and radiographic signs of relative root apex closure.<sup>11-13</sup>

Approaches to quantifying tooth/root development stage have been proposed in forensic dental practice with the aim of estimating age according to formation level of dental structures.<sup>14-20</sup> Such approaches include considering deviations from standard average parameters.<sup>14,17-20</sup> An alternative approach is to use forensic dental methods in endodontic practice that are based on the stage of tooth development before treatment.

The objective of this study was to evaluate the influence of pretreatment root development stage on the success

of apexification with the use of a modified forensic technique of estimating odontologic age.


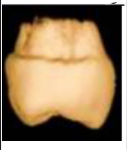






METHODS

In the clinical phase of the study, pediatric patients underwent endodontic treatment with apexification manipulation; a calcium hydroxide agent was used according to the algorithm described in previously published studies.<sup>12,13</sup> Apexification of maxillary and mandibular permanent incisors, first molars, and premolars was provided to patients with signs of irreversible pulp changes or chronic apical periodontitis. Duration of treatment varied from 6 to 24 months (average, 11 ± 0.6 months), depending on the stage of root development documented before the treatment (the earlier the root development stage, the longer the treatment). Pediatric patients at the University Dental Clinic (Uzhhorod National University, Uzhhorod, Ukraine) were selected on the basis of the following inclusion criteria: (1) the need for the apexification procedure because of pulp necrosis, irreversible pulpitis of different etiology, or chronic apical periodontitis in which open apex of root was diagnosed radiographically; (2) parents' agreement, on a modified patient informed consent form, to the proposed treatment and further monitoring; and (3) the absence of related clinical disorders that could influence the outcome of endodontic treatment of the problematic tooth. The final sample consisted of 43 patients, of whom 24 were boys and 19 were girls, aged 7 to 11 years.

In the experimental phase of this study, a modification of Demirjian et al.'s original age estimation technique<sup>16</sup> was used. The superimposition graphical principle was used to compare the radiologically documented developmental stage of the tooth with eight referent representations of tooth development stages described by Demirjian et al.<sup>14-16,18-20</sup> These comparisons were performed before and 12 months after endodontic treatment. The tooth stages are described in Table 1.<sup>16,17</sup>

Radiographs of each problematic tooth were obtained, with the use of Planmeca ProX (Planmeca) device, by the paralleling technique, which helps measure relative objective size parameters of the tooth. The proposed modified approach for improving the assessment of tooth development stage according to the radiological features involves taking digital radiographs of teeth, unification of tooth parameters by indicators of the standardized area of interest and plane orientation, contrast optimization and segmentation of the graphic image of the tooth, adaptation of object dimensional parameters to similarities in the reference graphical representations of Demirjian et al.'s stages of tooth development,<sup>16</sup> and further enhance the comparison by superimposition with the software MATLAB (The MathWorks, Inc., Natick, Mass.). This method was

Table 1. Representation of Demirjian et al.'s stages of tooth development

	<b>Stage A:</b> Calcification starting at the superior part of tooth crypt		<b>Stage E:</b> Root length formation < crown height
	<b>Stage B:</b> Formation of one or several cusps and outlined occlusion surface		<b>Stage F:</b> Root length ≥ crown height
	<b>Stage C:</b> Extension of enamel formation toward cervical regions		<b>Stage G:</b> Apical part of root still partially open
	<b>Stage D:</b> Crown formation completed up to cemento-enamel junction		<b>Stage H:</b> Apical end of root totally closed

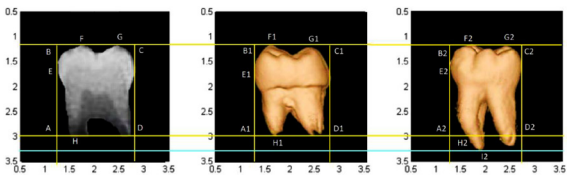
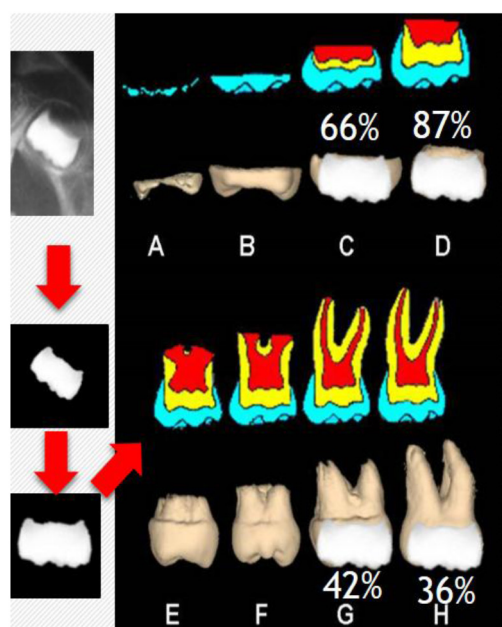


Figure 1. Schematic layout of computed comparison for radiograph of actual tooth with the possible stages of tooth development in the system proposed by Demirjian et al. in specific referent points. Process included obtaining pretreatment radiograph, further image modification, and further comparison with tooth development stages; three-dimensional pictures used only for in-site representation.

previously described by Goncharuk-Khomyn,<sup>20</sup> and the principle of superimposition used in this study was previously described by Goncharuk-Khomyn and Andrii.<sup>21</sup> For this research, both the method and the technique were modified for planimetric images in that the referent image was superimposed onto the study images according to specific referent points (Figure 1) and the square-contouring method (Figure 2).<sup>20</sup>

MATLAB software allows the user to automatically determine the level of similarity between the investigated graphic object and Demirjian et al.'s eight reference stages of development.<sup>16</sup> The results are expressed in means of percentages of superimposed points and contours.

In the analytical phase of the study, included the comparison of problematic teeth radiographs taken before treatment were compared with those taken 12 months after treatment, and the documented



**Figure 2.** Schematic layout of computed comparison between obtained radiograph of actual tooth and the possible stages of tooth development according to the system proposed by Demirjian et al. These representations were achieved with square-contouring superimposition.

radiographic changes in the root were compared to Demirjian et al.'s reference system.<sup>16</sup> This research was done to determine whether there was any correlation between the success of the apexification and the pretreatment root development stage assessed by radiography according to the principles of Demirjian et al.'s method.<sup>16</sup>

The study protocol was approved by the Dentistry Ethics Committee of Uzhhorod National University.

### Statistical Analysis

Pearson's  $r$  was used to measure any possible linear correlation between the stage of tooth development before treatment and the stage after treatment. Parameters of pretreatment and posttreatment tooth development stages were converted into numerical data for further statistical analysis, whereby each stage of development corresponded to specific numerical indicators from 1 to 8. Linear and quadratic regression analyses were performed to determine level of associations among gender, tooth, pretreatment tooth development stage, and Demirjian et al.'s<sup>16</sup> tooth stage G or H 12 months after treatment.<sup>22</sup> Level of significance was represented by  $p < 0.05$ . All statistical analysis was performed with Microsoft Excel software (Microsoft Office 2016, Microsoft, Redmond, Wash.).

## RESULTS

During the analysis, it was noted that of all the teeth that were documented before treatment to be at

developmental stage D, no further development of the teeth was noted in 11.2% of cases among boys or in 5.6% of cases among girls. Of the other teeth, 15.6% of cases among boys and 15.4% cases among girls achieved stage F; 18.1% of cases among boys and 15.5% of cases among girls achieved stage G; and 9.8% of cases among boys and 8.8% of cases among girls achieved stage H. On the other hand, in all the teeth documented before treatment to be at stage H, a full closing of apex was achieved. Detailed descriptions of each apexification result obtained among teeth with different pretreatment stages of development are listed in Table 2.

The liner and quadratic regressions analyses revealed no significant association between parameters of gender (male/female) and achieved tooth stage G or H or between tooth (molar, premolar, incisor) and achieved tooth stage G or H. However, statistically significant associations were found between pretreatment tooth development stage and achieved tooth development stage G or H among all study subjects with the same regression analysis methods (Table 3).

Because initial tooth development stage is correlated with age, as previously established by numerous authors,<sup>14,18-20</sup> the possibility of achieving stage G or H during apexification treatment was also statistically dependent on age ( $p < 0.05$ ). Such dependency is logical: The older is a child, the more progressive the tooth-specific pretreatment development stage is, which in turn is correlated with higher likelihood of achieving stage H after the apexification procedure.

The statistical analyses revealed a close covariance between the indicators for the pretreatment stage of development of the tooth and the possibility of successful apexification, which corresponds to the following dependencies: between pretreatment stage D and posttreatment stage E,  $r = 0.84$  ( $p < 0.05$ ); between pretreatment stage D and posttreatment stage F,  $r = 0.67$  ( $p < 0.05$ ); between pretreatment stage D and posttreatment stage G,  $r = 0.54$  ( $p < 0.05$ ); between pretreatment stage D and posttreatment stage H,  $r = 0.36$  ( $p > 0.05$ ); between pretreatment stage E and posttreatment stage F,  $r = 0.88$  ( $p < 0.05$ ); between pretreatment stage E and posttreatment stage G,  $r = 0.75$  ( $p < 0.05$ ); between pretreatment stage E and posttreatment stage H,  $r = 0.69$  ( $p < 0.05$ ); between pretreatment stage F and posttreatment stage G,  $r = 0.87$  ( $p < 0.05$ ); between pretreatment stage F and posttreatment stage H,  $r = 0.81$  ( $p < 0.05$ ); and between pretreatment stage G and posttreatment stage H,  $r = 0.91$  ( $p < 0.05$ ; Figure 3). Analysis of the results showed that the more advanced tooth development stage is before treatment, the stronger is the statistical probability of achieving stage H at the end of apexification therapy. This analysis was possible to perform because parameters for pretreatment and posttreatment tooth development stages could be converted into numerical

Table 2. Results of different tooth stages achieved after apexification

Stage of tooth development achieved after treatment (% of Cases)	Stage of tooth development before treatment								Total (%)
	E		F		G		H		
	Male (%)	Female (%)	Male (%)	Female (%)	Male (%)	Female (%)	Male (%)	Female (%)	
D	11.20	5.60	15.60	15.40	18.10	15.50	9.80	8.80	100.00
E	—	—	14.50	18.10	18.80	19.50	12.40	16.70	100.00
F	—	—	—	—	15.50	16.40	34.20	33.90	100.00
G					4.50	6.90	43.40	45.20	100.00
H							52.20	47.80	100.00

Table 3. Regressions comparisons gender, tooth, pre-treatment tooth development stage, and obtained tooth stage G or H by Demirjian et al.'s system

Parameters	Obtained tooth stage of Demirjian et al.'s system	Linear Regression Analysis	Quadratic Regression Analysis
Gender (male/female)	G	$p > 0.05$	$p > 0.05$
	H		
Tooth (molar, premolar, incisor)	G	$p > 0.05$	$p > 0.05$
	H		
Initial tooth development stage	G	$p < 0.05$	$p < 0.05$
	H		

data, whereby each stage of development corresponds to a specific numerical indicator.

DISCUSSION

Different endodontic status scales have been used to evaluate treatment quality during periods of monitoring with various clinical and instrumental diagnostic methods.<sup>23-28</sup> However, effectiveness of the apexification procedure in most clinical cases of endodontic treatment among children has been estimated by subjective assessment of radiographs that show no clinical signs of periapical lesions. By this way most of previously published studies approved the efficacy of calcium hydroxide agents and mineral trioxide aggregate (MTA) apical plugs use for the supporting root apex closure.<sup>13,24-26,28-30</sup>

In a systematic review, Chala et al. reported that in patients who underwent apexification with calcium hydroxide, the apical barrier was detected through tactile sensation of the operator during the process of detecting the apical stop; in several studies, this approach was supplemented by radiographic evaluation.<sup>25</sup> In patient who were treated with MTA plugs, apical barrier formation was assessed by defining a radiopaque bridge over the MTA plug zone. Recent systematic reviews and meta-analyses had not revealed a significant difference in effectiveness between calcium hydroxide and MTA for the apexification procedure; evaluation criteria included clinical signs

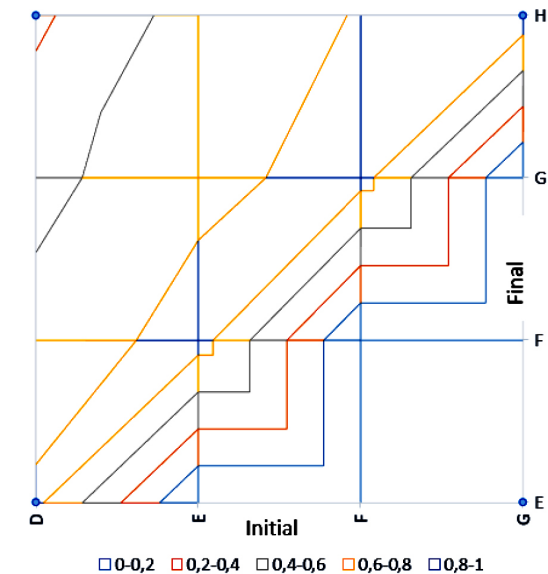


Figure 3. Interdependence of indicators of the initial (pretreatment) stage of tooth development (D, E, F, and G) and the final (posttreatment) stage of tooth development (E, F, G, and H) during apexification.

and radiographic evidence of apical barrier formation, but Chala et al. clearly stated that more studies are needed to evaluate factors influencing rates of success and failure with apexification.<sup>13,25,26</sup>

For a tooth on which endodontic treatment will be performed, the formation stage of the root remains one



of the determining factors for achieving success in the process of root apex closure, but quantification of the formation stage has been not described previously. In a retrospective cohort study, Alobaid and colleagues found that teeth with more immature stages of root development were subject to more adverse treatment effects than were teeth with more mature stages of root development.<sup>31</sup> This study did not reveal such a tendency, but it did demonstrate that teeth in earlier pretreatment stages of root development in Demirjian et al.'s system<sup>16</sup> had a lower statistical probability of reaching the final stage of root development. Rafter also mentioned that the size of the apical foramen opening, which depends on the stage of root development, should be considered in determining when endodontic dressing for apexification should be replaced.<sup>32</sup> Rafter also recommended that this principle be used for every individual treated tooth at each stage of development.<sup>32</sup> In this study, a modified forensic dental approach is proposed for evaluating the relationship between possible effective outcome of apexification and pretreatment root development stage.

Forensic dental approaches such as those of Haavikko<sup>32</sup> or Demirjian et al.<sup>16</sup> provide algorithms for categorizing tooth development stages that were traditionally estimated according to dental status.<sup>16-20</sup> It used to be difficult to justify implementing those approaches in clinical practice. Moreover, most clinicians disregard the difference between the chronological and dental ages of pediatric patients, but this difference plays a significant role in the choice between different treatment modalities.<sup>19</sup> An ideal model for any dental treatment in the pediatric population would include complex evaluation of patients whereby the numerically calculated and statistically substantiated coefficients and the degree of changes would be analyzed to provide the best results for the tooth-jaw relationship in general and the individual tooth specifically. This analysis in turn would reflect the role of forensic methods in clinical dental practice.<sup>19,20</sup> In this study, a dental forensic method of estimating tooth age in clinical practice was evaluated for ability to predict results of apexification among children. This represents a possible approach to quality control of endodontic treatment in pediatric patients.

Previous authors have described different approaches to assess root development stages objectively. Plascencia et al. proposed using the Cvek staging method to predict the outcomes of endodontic treatment of permanent teeth with necrotic pulps and open apices.<sup>29</sup> Even though this methodological approach was effective, the comparison of radiographic results with Cvek's stages of tooth development was subjective. The approach, with a modification of Demirjian et al.'s method,<sup>16</sup> includes use of MATLAB software, which allows users to determine automatically the level of similarity

between the radiographic appearance and the eight reference stages of tooth development.

The data obtained in this study demonstrate that classical algorithms for endodontic treatment of teeth with incomplete root formation can be used to predict successful results for teeth in pretreatment stages F, G, and H with a statistically approved level of probability.<sup>11,12,26</sup> In cases of endodontic treatment of teeth that are in pretreatment stages D and E, protocols of iatrogenic intervention need to be modified. Regenerative endodontics methods might provide such modification, serving as alternatives to classical endodontic treatment modalities.<sup>28,33</sup>

Limitations of this study include the small size of the study sample and the complicated protocol of image processing during superimposition with Demirjian et al.'s referent stages.<sup>16</sup> Also, longer monitoring is needed to verify the prognostic association between pretreatment stage of tooth development and success of apexification procedure. In several studies, a 6-month period was enough to conclude that apexification was effective,<sup>34,35</sup> but in other studies, a 6-year screening period was used to determine successful apex closure after apexification.<sup>36</sup>

Future study of this topic should be devoted to the further statistical analysis of deviations between chronological and dental age in the pediatric population. Investigators should search for a relationship between absolute apex closure and the interpretation of developmental stage H, which represents full formation of a tooth.

## CONCLUSION

A forensic dental approach for categorizing tooth developmental stages, with proposed modifications, could be used in dental practice to help quantify the level of root closure after an apexification procedure. According to the results of this study, there is a close covariance between the pretreatment developmental stages F, G, and H originally proposed by Demirjian et al.<sup>16</sup> and the possibility of successful apexification outcome after endodontic treatment with calcium hydroxide agent. In cases of endodontic treatment of teeth that are in developmental stages D and E before treatment, endodontic protocols must be modified to produce more positive outcomes. The implementation of perspective regenerative principles may enable such modification.

## CONFLICT OF INTEREST

The author declares that there were no conflicts of interest related to this study.

## REFERENCES

- Kostenko S, Dzupa P, Levandovskiy R, Bun Y, Mishalov V, Goncharuk-Khomyn M. Optimized Approach of Dental Composites Identification with The Use of Original Spectrophotometric Algorithm. *J Int Med Res.* 2018; 11(2):403-8.
- John J, Yatim FM, Mani SA. Measuring service quality of public dental health care facilities in Kelantan, Malaysia. *Asia Pac J Public Health.* 2011; 23(5):742-53.
- Chang WJ, Chang YH. Patient satisfaction analysis: Identifying key drivers and enhancing service quality of dental care. *Journal of Dental Sciences.* 2013; 8(3):239-47.
- Gillen BM, Looney SW, Gu LS, Loushine BA, Weller RN, Loushine RJ, Tay FR. Impact of the quality of coronal restoration versus the quality of root canal fillings on success of root canal treatment: a systematic review and meta-analysis. *J Endod.* 2011; 37(7):895-902.
- Tabassum S, Khan FR. Failure of endodontic treatment: The usual suspects. *Eur J Dent.* 2016; 10(1):144.
- Venskutonis T, Plotino G, Tocci L, Gambarini G, Maminskis J, Juodzbals G. Periapical and endodontic status scale based on periapical bone lesions and endodontic treatment quality evaluation using cone-beam computed tomography. *J Endod.* 2015; 41(2):190-6.
- Correa MB, Peres MA, Peres KG, Horta BL, Barros AJ, Demarco FF. Do socioeconomic determinants affect the quality of posterior dental restorations? A multilevel approach. *J Dent.* 2013; 41(11):960-7.
- Sonbul H, Birkhed D. Risk profile and quality of dental restorations: A cross-sectional study. *Acta Odontol Scand.* 2010; 68(2):122-8.
- Michaud PL, de Grandmont P, Feine JS, Emami E. Measuring patient-based outcomes: is treatment satisfaction associated with oral health-related quality of life? *J Dent.* 2012; 40(8):624-31.
- Fromentin O, Boy-Lefevre ML. Quality of prosthetic care: patients' level of expectation, attitude and satisfaction. *Eur J Prosthodont Restor Dent.* 2001; 9(3-4):123-9.
- Shabahang S. Treatment options: apexogenesis and apexification. *J Endod.* 2013; 39(3):S26-9.
- Corbella S, Ferrara G, El AK, Taschieri S. Apexification, apexogenesis and regenerative endodontic procedures: a review of the literature. *Minerva stomatol.* 2014; 63(11-12):375-89.
- Lin JC, Lu JX, Zeng Q, Zhao W, Li WQ, Ling JQ. Comparison of mineral trioxide aggregate and calcium hydroxide for apexification of immature permanent teeth: A systematic review and meta-analysis. *J Formos Med Assoc.* 2016; 115(7):523-30.
- Willems G, Van Olmen A, Spiessens B, Carels C. Dental age estimation in Belgian children: Demirjian's technique revisited. *J Forensic Sci.* 2001; 46(4):893-5.
- Maber M, Liversidge HM, Hector MP. Accuracy of age estimation of radiographic methods using developing teeth. *Forensic Sci Int.* 2006; 159:S68-73.
- Demirjian A, Goldstein H, Tanner JM. A new system of dental age assessment. *Hum Biol.* 1973; 211-27.
- Duangto P, Janhom A, Prasitwattanaseree S, Mahakkanukrauh P, Iamaroon A. Age estimation methods in forensic odontology. *J. dent. Indones.* 2016; 23(3):74-80.
- Haavikko K. Tooth formation age estimated on a few selected teeth. A simple method for clinical use. *Procc Finn Dent Soc.* 1974; 70(1):15-9.
- Goncharuk-Khomyn M. Modification of dental age estimation technique among children from transcarpathian region. *J Int Med Res.* 2017; 10(3):851-5.
- Goncharuk-Khomyn MY. Efficiency analysis of the improved method for the assessment of morphological stage of tooth development by the rentgenological signs. *Morphologia.* 2017; 11(4):28-34.
- Goncharuk-Khomyn M, Andrii K. Evaluation of peri-implant bone reduction levels from superimposition perspective: Pilot study among Ukrainian implantology practice. *Pesquisa Brasileira em Odontopediatria e Clinica Integrada.* 2018; 18(1):3856.
- Peat J, Barton B. Medical statistics: A guide to data analysis and critical appraisal. John Wiley & Sons. 2018
- Huomonen S, Ørstavik D. Radiographic follow-up of periapical status after endodontic treatment of teeth with and without apical periodontitis. *Clin Oral Investig.* 2013; 17(9):2099-104.
- Kirkevang LL, Ørstavik D, Wenzel A, Væth M. Prognostic value of the full-scale periapical index. *Int Endod J.* 2015; 48(11):1051-8.
- Chala S, Abouqal R, Rida S. Apexification of immature teeth with calcium hydroxide or mineral trioxide aggregate: systematic review and meta-analysis. *Oral Surg Oral Med Oral Pathol Oral Radiol Endod.* 2011; 112(4):e36-42.
- Guerrero F, Mendoza A, Ribas D, Aspiazu K. Apexification: A systematic review. *J Conserv Dent.* 2018; 21(5):462.
- Tate AR. Calcium hydroxide or mineral trioxide aggregate may be used for the apexification of immature teeth. *J Evid Based Dent Pract.* 2012; 12(1):24-5.
- Pramila R, Muthu MS. Regeneration potential of pulp-dentin complex: Systematic review. *J Conserv Dent.* 2012; 15(2):97.

29. Plascencia H, Díaz M, Gascón G, Garduño S, Guerrero-Bobadilla C, Márquez-De Alba S, González-Barba G. Management of permanent teeth with necrotic pulps and open apices according to the stage of root development. *J Clin Exp Dent.* 2017; 9(11):e1329.
30. Felipe WT, Felipe MCS, Rocha MJC. The effect of mineral trioxide aggregate on the apexification and periapical healing of teeth with incomplete root formation. *Int Endod J.* 2006; 39(1):2-9.
31. Alobaid AS, Cortes LM, Lo J, Nguyen TT, Albert J, Abu-Melha AS, Gibbs JL. Radiographic and clinical outcomes of the treatment of immature permanent teeth by revascularization or apexification: a pilot retrospective cohort study. *J Endod.* 2014; 40(8):1063-1070.
32. Rafter M. Apexification: a review. *Dent Traumatol.* 2005; 21(1):1-8.
33. Torabinejad M, Nosrat A, Verma P, Udochukwu O. Regenerative endodontic treatment or mineral trioxide aggregate apical plug in teeth with necrotic pulps and open apices: a systematic review and meta-analysis. *J Endod.* 2017; 43(11): 1806-20.
34. Pane ES. Apexification of a tooth with dens invaginatus (a case report). *J dent Indones.* 2015; 10(3):769-73.
35. Febriyanti F, Soemartono SH. Apexification on permanent molar of nine-year-old patient. *J dent Indones.* 2008; 13(1):111-6.
36. Silva RV, Silveira FF, Nunes E. Apexification in non-vital teeth with immature roots: Report of two cases. *Iran Endod J.* 2015; 10(1):79.

(Received February 2, 2019; Accepted April 22, 2019)