

8-31-2019

## Effectiveness of Topical Steroids in Treating Herpes-Associated Erythema Multiforme and Review of Topical Steroids

Kobkan Thongprasom

*Department of Oral Medicine, Faculty of Dentistry, Chulalongkorn University, Bangkok 1033, Thailand,*  
kobkan.t@chula.ac.th

Sireerat Sooampon

*Department of Pharmacology, Faculty of Dentistry, Chulalongkorn University, Bangkok 1033, Thailand*

Follow this and additional works at: <https://scholarhub.ui.ac.id/jdi>

---

### Recommended Citation

Thongprasom, K., & Sooampon, S. Effectiveness of Topical Steroids in Treating Herpes-Associated Erythema Multiforme and Review of Topical Steroids. *J Dent Indones.* 2019;26(2): 114-118

This Case Report is brought to you for free and open access by the Faculty of Dentistry at UI Scholars Hub. It has been accepted for inclusion in Journal of Dentistry Indonesia by an authorized editor of UI Scholars Hub.

## **CASE REPORT**

# **Effectiveness of Topical Steroids in Treating Herpes-Associated Erythema Multiforme and Review of Topical Steroids**

**Kobkan Thongprasom<sup>1</sup>, Sireerat Sooampon<sup>2</sup>**

<sup>1</sup>*Department of Oral Medicine, Faculty of Dentistry, Chulalongkorn University, Bangkok 1033, Thailand*

<sup>2</sup>*Department of Pharmacology, Faculty of Dentistry, Chulalongkorn University, Bangkok 1033, Thailand*  
Correspondence e-mail to: kobkan.t@chula.ac.th

## **ABSTRACT**

**Objective:** To show the effectiveness of various potent topical steroids in treating severe oral ulcerations without any side-effects. Potent topical steroids are recommended as an alternative treatment for severe oral ulcerations in Herpes associated erythema multiforme (HAEM) patients. **Case report:** A 50-year-old female presented at the Oral Medicine clinic at the Faculty of Dentistry, Chulalongkorn University, Bangkok with a chief complaint of severe pain in her oral cavity and lips for 1 week. She had no systemic diseases, except for vertigo, and was currently taking cetirizine hydrochloride. An oral examination revealed a hemorrhagic crust on her lips, scaly, large ulcerations on the upper labial mucosa, and multiple oral ulcerations on the right and left buccal mucosa. She had limited mouth opening and difficult in eating. She was treated with benzydamine hydrochloride mouthwash, triamcinolone acetonide 0.1% mouthwash, and fluocinolone acetonide 0.1% solution. The patient's pain and severe oral lesions gradually reduced after treatment for one week. At the one month follow-up, all lesions had completely disappeared and the laboratory investigation report showed that she was Herpes simplex virus Ab IgG type I and Type II positive; therefore, the diagnosis in this case was HAEM.

Key words: herpes, erythema multiforme, fluocinolone acetonide, oral, triamcinolone acetonide

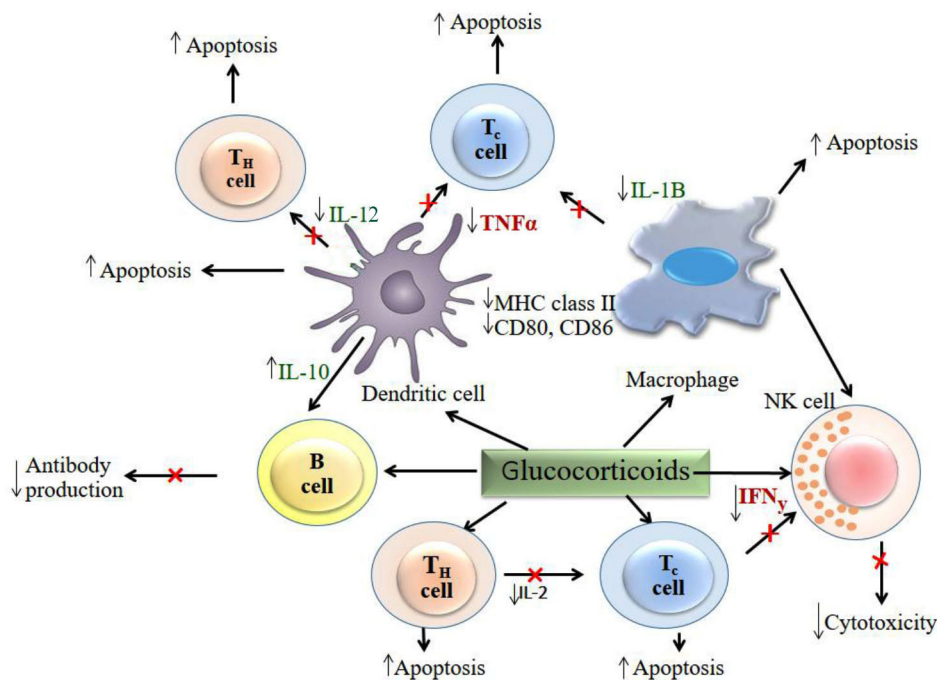
How to cite this article: Thongprasom K, Sooampon S. Effectiveness of topical steroid in treating herpes-associated erythema multiforme and review of topical steroids. *J Dent Indones.* 2019;26(2):114-118

## **INTRODUCTION**

Steroids have been widely used either systemically or topically to treat various oral mucosal diseases such as oral lichen planus (OLP),<sup>1,2</sup> oral ulceration,<sup>3</sup> oral lichenoid lesion,<sup>4</sup> mucous membrane pemphigoid,<sup>5</sup> pemphigus,<sup>6</sup> and erythema multiforme (EM).<sup>7</sup> Steroids inhibit the expression of prostaglandins and many proinflammatory cytokines, thus steroids reduce pain and inflammation. Moreover, steroids have an indirect effect on T helper cells and a direct effect on B cells, therefore antibody production is reduced. Moreover, glucocorticoids act on immune cells both directly and indirectly to suppress the induction of pro-inflammatory responses. Steroids upregulate the expression of anti-inflammatory proteins, while downregulating the expression of proinflammatory proteins (Figure 1). Interestingly, the therapeutic use of the topical steroid dexamethasone resulted in significantly decreased saliva levels of proinflammatory cytokines, such as tumor necrosis factor-alpha, interleukin-1-alpha (IL-

1- $\alpha$ ), IL-6, and IL-8, in whole unstimulated saliva in subjects with erosive OLP.<sup>8</sup>

Various methods are used to treat severe oral lesions either systemically or topically. Many forms of steroids are available for treating oral mucosal diseases, such as oral, injection, topical, inhalation, and mouthwashes. Topical steroids are an alternative method of drug delivery that are more targeted to the lesions compared with injection or systemic steroids. Because the oral mucosa is highly vascularized, drugs absorbed through the oral mucosa directly enter the systemic circulation.<sup>9,10</sup> However the absorption is much lower compared with systemic treatment, resulting in fewer systemic side-effects.<sup>11</sup> Using topical steroids to treat oral mucosal diseases is effective because they can penetrate directly into the oral lesions with minimal side-effects compared with systemic steroids.



**Figure 1.** Glucocorticoids act on immune cells both directly and indirectly to suppress the induction of pro-inflammatory responses. (Modified from Nature Publishing Group Nature Reviews/ Immunology, 2006)

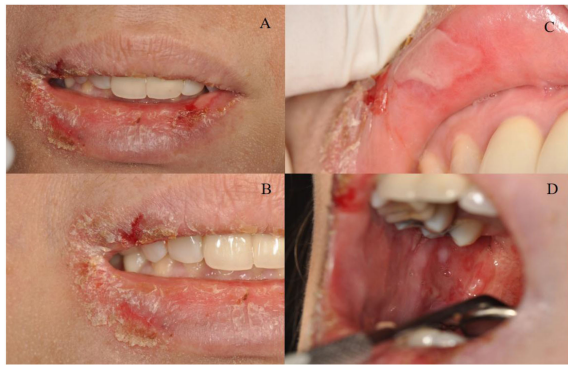
**Table 1.** Various topical steroids' potency, class, and formulation\*

Potency	Class	Topical corticosteroid	Formulation
Ultra high	I	Clobetasol propionate	Cream, 0.05%
High	II	Betamethasone dipropionate	Ointment, 0.05%
		Fluocinonide	Cream, ointment or gel, 0.05%
Moderate	III	Betamethasone dipropionate	Cream, 0.05%
		Betamethasone valerate	Ointment, 0.1%
		Fluocinolone acetonide	Orabase, 0.1%
		Triamcinolone acetonide	Ointment, 0.1%
Moderate	IV	Fluocinolone acetonide	Ointment, 0.025%
		Triamcinolone acetonide	Cream, 0.1%
		V	Betamethasone valerate
Fluocinolone acetonide	Cream, 0.025%		
Triamcinolone acetonide	Lotion, 0.1%		
Low	VI	Betamethasone valerate	Lotion, 0.05%
		Fluocinolone acetonide	Solution, 0.01%
Low	VII	Dexamethasone sodium phosphate	Cream, 0.1%
		Hydrocortisone acetate	Cream, 1%

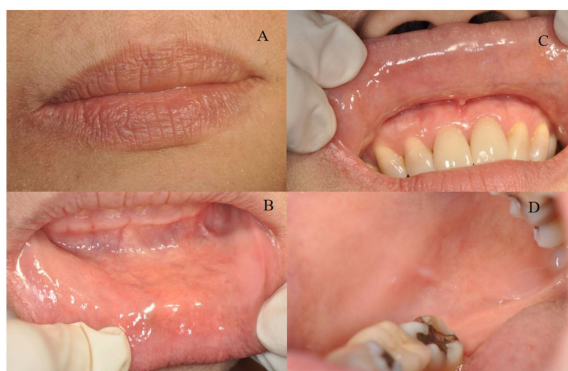
\*Modified from Essential Medicines and Health Products Information Portal A World Health Organization resource. WHO Model Prescribing Information: Drugs Used in Skin Diseases, 1997.

Many topical steroids are now available in different preparations. The classification of a topical steroid based on potency may vary depending on the formulation and concentration.<sup>12</sup> In general, ointments are more potent compared with creams or lotions. Fluocinolone acetonide 0.1% in orabase (FAO) and triamcinolone acetonide (TA) 0.1% ointment are high potency topical

steroids. In contrast, fluocinolone acetonide 0.01% in solution (FAS) and dexamethasone sodium phosphate 0.1% cream are low potency steroids, whereas clobetasol propionate 0.05% cream is the highest potency topical steroid. Therefore, the same topical steroid in a different formulation or concentration will have different potencies (Table 1).



**Figure 2.** Hemorrhagic crust and scaly lips (A, B) with large ulceration on the upper labial mucosa (C), and limited mouth opening (D).



**Figure 3.** One month after treatment with benzydamine hydrochloride mouthwash, TA 0.1% mouthwash, and FAS 0.1% solution, all mucosa appeared normal (A, B, C, D).

In this report, we present the case of a 50-year-old female with severe oral ulceration of Herpes associated erythema multiforme (HAEM) that demonstrated that potent topical steroids can be effectively used to treat these severe oral lesions without side-effects.

## CASE REPORT

A 50-year-old female came to the Oral Medicine clinic at the Faculty of Dentistry, Chulalongkorn University, Bangkok in August, 2017 with a chief complaint of severe pain in her oral cavity and lips for 1 week. She had no serious systemic diseases except vertigo and was currently taking cetirizine (Zyrtec). An oral examination revealed a hemorrhagic crust on her lips, scaly, large ulcerations on the upper labial mucosa, and multiple oral ulcerations on the right and left buccal mucosa (Fig. 2 A, B, C, D). She had limited mouth opening. She was treated with benzydamine hydrochloride mouthwash and TA 0.1% mouthwash three times a day. FAS 0.1% solution was applied on her lips three times a day. The lesions in her oral cavity and lips gradually improved after treatment with topical

steroids for one week. Her pain was also reduced when using benzydamine hydrochloride and topical steroids for 1 week. At the one-month follow-up, all lesions had completely disappeared (Figure 3 A, B, C, D) and the laboratory investigation report showed that she was Herpes simplex virus (HSV) Ab IgG type I and Type II positive; therefore, the diagnosis in this case was Herpes associated erythema multiforme (HAEM). No side effects from the topical steroid treatments were observed in this case.

## DISCUSSION

Erythema multiforme (EM) is a self-limited hypersensitivity reaction involving the skin and mucous membranes. Herpes simplex virus is the most common condition associated with recurrent EM; however, in most cases a cause cannot be identified. More than half of the patients did not have an identifiable cause for recurrent EM, and the frequency of a diagnosis of HSV associated with HAEM varies between studies.<sup>13, 14</sup> When target lesions are not present, the diagnosis of EM is very difficult. For more severe cases of EM, supportive care and treatment with systemic steroids or other immunosuppressive agents are necessary. Furthermore, in recurrent EM cases, chronic suppressive antiviral therapy may be indicated.<sup>15</sup>

When there is mucosal involvement of HSV or EM, severe symptoms, or a high rate of recurrence, treatment and prophylaxis with antiviral agents may be considered. Oral acyclovir has shown to be effective for prophylaxis, with valacyclovir and famciclovir providing alternate treatment options.<sup>16</sup>

In the present case, the lesions presented in the oral cavity and lips, however, there were no skin lesions or target lesions. The oral manifestation of severe generalized ulceration and hemorrhagic crusts on the lips are pathognomonic signs of EM. Moreover, positive laboratory results for HSV Ab IgG type I and Type II can confirm the diagnosis of HAEM. Potent topical steroids in various forms, such as TA 0.1% mouthwash and FAS 0.1%, were effective in the treatment of the severe oral lesions in this case.

In summary, the advantages of topical steroids are that they rapidly reduce pain and inflammation. Topical steroids were successfully used in this case and the oral lesions showed complete resolution without any side-effects during the 1 month of treatment. A previous report demonstrated that the topical steroids FAS or FAO 0.1% were safe and effective in treating HAEM in a pregnant patient.<sup>7</sup> Therefore, treating severe oral lesions with short-term potent topical steroids is recommended because they have been found to be effective, safe, and without side-effects. Interestingly, one rare case of Plasma cell mucositis showed no response to any medications, in contrast,

the refractory oral lesions showed marked improvement after treatment with potent topical steroids.<sup>17</sup> However, side-effects of potent topical steroids used in treating oral lesions, such as pseudomembranous candidiasis, erythematous candidiasis may occur, however, these can be effectively treated with topical antifungals. Moreover, although hyperpigmentation of the oral mucosa with topical steroid treatment has been observed, the pigmentation gradually reduced over long-term follow-up.<sup>18</sup>

It is important to differential diagnosis between primary herpes simplex infection from HAEM, particularly in children. When HAEM occurs in children, the treatment plan will be supportive care and pain control. Non steroidal anti-inflammatory drug (NSAIDs) may be used for more immediate pain relief. If the patients have difficulty eating and drinking, a topical anesthetic mouthwash may be administered before meals for treating oral lesions. Recent report showed that the topical prophylactic treatment in HAEM patient with acyclovir does not seem to prevent further episodes of erythema multiforme.<sup>19</sup> Because of its similar symptoms, it is difficult to differential diagnosis of herpes simplex infection from HAEM in its early stage.

Primary herpes simplex infection in children present with a history of generalized prodromal symptoms including fever, headache, malaise and nausea which precede the local lesions. Erythema and clusters of pinhead vesicles and/or ulcers appear on the oral mucosa within a few days of prodromal symptoms.<sup>20</sup> This is helpful in differentiating this viral infection from HAEM. Moreover, submandibular and cervical lymph nodes in patients with primary herpes simplex infection are characteristically enlarged and tender, while HAEM patients may not show lymphadenopathy. An important diagnostic criteria in primary herpes simplex is the appearance of a generalized acute marginal gingivitis. Several small gingival ulcers are often present.<sup>20,21</sup> Therefore, clinician should pay attention in such patients for proper treatment and management.

## CONCLUSION

Potent topical steroids demonstrated their effectiveness and are recommended for treating severe oral ulcerations in HAEM patients. No side-effects were found during follow-up. These topical steroids rapidly reduce pain, are safe, low cost, and without serious side-effects.

## CONFLICT OF INTERESTS

All authors declared no conflict of interests.

## ACKNOWLEDGEMENTS

This manuscript is a part of an integrated lecture of oral presentations entitled "Effectiveness and side effects of steroids in the treatment of oral mucosal diseases" for the "3<sup>rd</sup> International Conference on Global Health (ICGH) that was held in conjunction with the 3<sup>rd</sup> International Workshop on Dental Research (IWDR) and the 1<sup>st</sup> International Seminar on Clinical and Research in Dentistry (ISCaRD)", Bali, Indonesia during 16 September, 2018. We thank the Research Unit in Oral Diseases, Chulalongkorn University and the Oral Medicine staff for long term support. We thank Ms. Sarinya Suphunpong, Pharmacology Department, Faculty of Dentistry, Chulalongkorn University, Bangkok, Thailand for preparing the topical steroids used in treating the oral lesions. We also thank Dr. Kevin Tompkins for reviewing and editing this manuscript.

## REFERENCES

1. Thongprasom K, Dhanuthai K. Review of steroids in the treatment of oral lichen planus. *J Oral Sci.* 2008;50(4):377-85.
2. Lodi G, Carrozzo M, Furness S, Thongprasom K. Interventions for treating oral lichen planus: a systematic review. *Br J Dermatol.* 2012;166(5):938-47.
3. Lui C, Zhou Z, Liu G, Wang Q, Chen J, Wang L et al. Efficacy and safety of dexamethasone ointment on recurrent aphthous ulceration. *Am J Med.* 2012;125(3): 292-301.
4. Thongprasom K, Sessririsombat S, Singkharotai K, Vathanasanti A, Subbalek K. Topical steroids and CO<sub>2</sub> laser in the treatment of refractory oral lichenoid drug reaction and lichenoid contact lesion: a case report. *Acta Stomatol Croat.* 2014;48 (3):224-9.
5. Carrozzo M, Carbone M, Broccoletti R, Garzino-Demo P, Gandolfo S. Therapeutic management of mucous membrane pemphigoid. Report of 11 cases. *Minerva Stomatol.* 1997;46 (10):553-9.
6. Neill BC, Liu D, Rajpara AN, Aires DJ. Treating gingival pemphigus vulgaris with cotton balls soaked in topical steroid ointment. *J Am Acad Dermatol.* 2017;76 (4):e119.
7. Thongprasom K. Treatment of a Pregnant Patient with Herpes Associated Erythema Multiforme (HAEM): A case report. *Acta Stomatol Croat.* 2016;50(3):265-8.
8. Rhodus NL, Cheng B, Bowles W, Myers S, Miller L, Ondrey F. Proinflammatory cytokine levels in saliva before and after treatment of (erosive) oral lichen planus with dexamethasone. *Oral Dis.* 2006;12(2):112-6.
9. Sankar V, Hearnden V, Hull K, Juras DV, Greenberg MS, Kerr AR, et al. Local drug

- delivery for oral mucosal diseases: challenges and opportunities. *Oral Dis.* 2011;17 (Suppl 1):73–84.
10. Shojaei AH. Buccal mucosa as a route for systemic drug delivery: a review. *J Pharm Pharm Sci.* 1998;1(1):15–30.
  11. Dhar S, Seth J, Parikh D. Systemic side-effects of topical corticosteroids. *Indian J Dermatol.* 2014;59(5):460-4.
  12. Essential Medicines and Health Products Information Portal. A World Health Organization resource Organization resource. WHO Model Prescribing Information: Drugs Used in Skin Diseases, 1997.
  13. Orgaz-Molina J, Arias-Santiago S. Erythema multiforme associated with herpes labialis. *CMAJ.* 2013; 185(16):1428.
  14. Wetter DA, Davis MD. Recurrent erythema multiforme: clinical characteristics, etiologic associations, and treatment in a series of 48 patients at Mayo Clinic, 2000 to 2007. *J Am Acad Dermatol.* 2010; 62(1):45 – 53.
  15. Hashemi DA, Carlos C, Rosenbach M. Herpes-Associated Erythema Multiforme. *JAMA Dermatol.* 2018; doi: 10.1001/jamadermatol.2018.3973.
  16. Woo SB, Challacombe SJ. Management of recurrent oral herpes simplex infections. *Oral Surg Oral Med Oral Pathol Oral Radiol Endod.* 2007;103 (Suppl 12): e1 – 18.
  17. Wongtim K, Subbalekha K, Chaisuparat R, Thongprasom K. Plasma cell mucositis: an unusual case. *AJOM.*2018; 4(2):18-23.
  18. Thongprasom K. A review of the effectiveness and side-effects of fluocinolone acetonide 0.1% in the treatment of oral mucosal diseases. *Acta Stomatol Croat.* 2017; 51(3):240-7.
  19. Lerch M, Mainetti C, Terziroli Beretta-Piccoli B, Harr T. Current Perspectives on Erythema Multiforme. *Clin Rev Allergy Immunol.*2018 ;54(1):177-84.
  20. Woo SB, Greenberg MS. Ulcerative, Vesicular, and Bullous Lesions. In: Greenberg MS editor. *Burket's Oral Medicine.* 11<sup>th</sup> edition. Hamilton: BC Decker Inc; 2007. p. 43-6.
  21. Neville BW, Damm DD, Allen CM, Chi AC. *Oral and Maxillofacial Pathology.* 4<sup>th</sup> edition, St. Louis: Saunders Elsevier; 2016. p. 225-30.

(Received June 13, 2019; Accepted August 13, 2019)