

6-30-2016

Acquired vulvar lymphangioma: Report of two cases

Indah Widyasari

Department of Dermatology and Venereology, Faculty of Medicine, Universitas Indonesia, dr. Cipto Mangunkusumo National Hospital, Jakarta

Hafiza Fathan

Department of Dermatology and Venereology, Faculty of Medicine, Universitas Indonesia, dr. Cipto Mangunkusumo National Hospital, Jakarta

Larisa Paramitha Wibawa

Department of Dermatology and Venereology, Faculty of Medicine, Universitas Indonesia, dr. Cipto Mangunkusumo National Hospital, Jakarta

See next page for additional authors

Follow this and additional works at: <https://scholarhub.ui.ac.id/jdvi>



Part of the [Dermatology Commons](#), [Integumentary System Commons](#), and the [Skin and Connective Tissue Diseases Commons](#)

Recommended Citation

Widyasari, Indah; Fathan, Hafiza; Wibawa, Larisa Paramitha; Cipto, Herman; Sampurna, Adhimukti T.; and Sirait, Sondang Pandjaitan (2016) "Acquired vulvar lymphangioma: Report of two cases," *Journal of General - Procedural Dermatology & Venereology Indonesia*: Vol. 1: Iss. 2, Article 6.

DOI: 10.19100/jdvi.v1i2.35

Available at: <https://scholarhub.ui.ac.id/jdvi/vol1/iss2/6>

This Article is brought to you for free and open access by the Faculty of Medicine at UI Scholars Hub. It has been accepted for inclusion in Journal of General - Procedural Dermatology & Venereology Indonesia by an authorized editor of UI Scholars Hub.

Acquired vulvar lymphangioma: Report of two cases

Authors

- Indah Widyasari
Department of Dermatology and Venereology, Faculty of Medicine, Universitas Indonesia, dr. Cipto Mangunkusumo National Hospital, Jakarta
- Hafiza Fathan
Department of Dermatology and Venereology, Faculty of Medicine, Universitas Indonesia, dr. Cipto Mangunkusumo National Hospital, Jakarta
- Larisa Paramitha Wibawa
Department of Dermatology and Venereology, Faculty of Medicine, Universitas Indonesia, dr. Cipto Mangunkusumo National Hospital, Jakarta
- Herman Cipto
Department of Dermatology and Venereology, Faculty of Medicine, Universitas Indonesia, dr. Cipto Mangunkusumo National Hospital, Jakarta
- Adhimukti T. Sampurna
Department of Dermatology and Venereology, Faculty of Medicine, Universitas Indonesia, dr. Cipto Mangunkusumo National Hospital, Jakarta
- Sondang Pandjaitan Sirait
Department of Dermatology and Venereology, Faculty of Medicine, Universitas Indonesia, dr. Cipto Mangunkusumo National Hospital, Jakarta

Case Report

Acquired vulvar lymphangioma: Report of two cases

Indah Widyasari, Hafiza Fathan, Larisa Paramitha Wibawa, Herman Cipto,
Adhimukti T Sampurna, Sondang Pandjaitan Sirait

Department of Dermatology and Venereology, Faculty of Medicine, Universitas Indonesia,
dr. Cipto Mangunkusumo National Hospital, Jakarta

email: indah_widyasari@yahoo.com

Abstract

Vulvar lymphangioma is a rare case and often being misdiagnosed as genital wart. This acquired disorder manifests as dilatation of superficial lymph vessel due to obstruction. It is caused by urogenital infection and most often occurs following surgery and radiotherapy of cervical cancer. The diagnosis is established based on clinical and histopathological features. Treatment aimed to eliminate the cause of obstruction. This article reports two cases of vulvar lymphangioma found in our Hospital.

First case was a 43-year-old female with a history of surgery and radiation for cervical cancer 10 years ago presented with vesicular skin lesion in genital area, oozing copious clear fluid since 4 years ago. There are multiple lenticular vesicles containing clear fluid in vulvar area accompanied with bilateral lymphedema of lower extremities. Histopathological features demonstrated dilated superficial lymph vessels.

Second case was a 44-year-old female with enlargement of lower abdomen with vesicular lesion containing clear fluid in genital area since 3 years ago. Abdominal USG showed enlarged inguinal lymph node. Histopathological features demonstrated dilated superficial lymph vessels. The treatment for both cases were gradual electrosurgery.

In both cases, vulvar dermis' superficial lymph node dilatation caused the skin lesions. Obstruction of lymph vessel due to radiation and surgery for cervical cancer in the first case and of inguinal lymph node in the second case lead to increased lymphatic pressure in the dermis and later on the dilatations. The treatment in both cases using electrical excision produced good responses; however, we should be attentive on recurrent case.

Keywords: acquired vulvar lymphangioma, dilatation of dermal lymph vessels, electrosurgery

Abstrak

Limfangioma vulva didapat merupakan kasus yang jarang ditemukan dan sering salah diagnosis sebagai kutil kelamin. Manifestasi klinis kelainan didapat ini berupa dilatasi pembuluh limfe superfisial akibat adanya sumbatan. Kelainan terjadi akibat infeksi urogenital dan tersering pascaoperasi serta radioterapi kanker serviks. Penegakan diagnosis berdasarkan gambaran klinis dan histopatologis. Tatalaksana utama adalah menghilangkan penyebab sumbatan. Makalah ini melaporkan dua kasus limfangioma vulva didapat pada institusi kami.

Kasus pertama adalah seorang perempuan, 43 tahun dengan riwayat operasi dan radiasi kanker serviks 10 tahun lalu terdapat bintil di kemaluan yang mudah pecah serta mengeluarkan cairan bening sejak 4 tahun yang lalu. Terdapat vesikel berisi cairan bening multipel lentikuler pada vulva disertai dengan limfedema tungkai bawah bilateral. Gambaran histopatologis tampak dilatasi pembuluh limfe superfisial.

Kasus kedua adalah seorang perempuan, 44 tahun dengan pembesaran abdomen bawah terdapat bintil berisi cairan bening pada kemaluan sejak 3 tahun yang lalu. USG abdomen ditemukan pembesaran kelenjar getah bening inguinal. Gambaran histopatologis terdapat dilatasi pembuluh limfe superfisial. Tatalaksana kedua kasus tersebut dilakukan dengan bedah listrik bertahap pada lesi kulit.

Kelainan yang mendasari lesi kulit pada kedua kasus adalah dilatasi pembuluh limfe superfisial dermis vulva. Sumbatan pembuluh limfe akibat radiasi dan operasi kanker serviks pada kasus 1 dan sumbatan pada kelenjar getah bening inguinal pada kasus 2, menyebabkan peningkatan tekanan pembuluh limfatik dermis. Beberapa modalitas terapi untuk menghilangkan lesi diharapkan memberi hasil akhir yang baik secara kosmetis, mencegah kekambuhan, dan infeksi. Tatalaksana pada kedua kasus menggunakan bedah listrik memberikan respon baik, namun perlu waspada adanya kekambuhan.

Kata kunci : limfangioma vulva didapat, dilatasi pembuluh limfe dermis, bedah listrik

Introduction

Acquired lymphangioma is a secondary benign skin tumor due to dilatation of dermal lymphatic vessels.¹⁻² This type of lymphangioma is included as secondary circumscriptum lymphangioma. The most common etiologies for this disorder are infection, radiotherapy and surgical procedure that may cause a defect in the lymph tract.³ It is commonly found in oral mucosa, tongue, extremities, inguinal fold, axilla, body trunk, scrotum and penis. Lymphangioma rarely occurs in the vulva, and therefore, it is commonly misdiagnosed as condyloma acuminata, molluscum contagiosum, and tuberculosis verrucosa cutis.² There are 73 cases have been reported in the literature, but no case of vulvar lymphangioma has been reported in Indonesia. There are five cases of acquired vulvar lymphangioma during 2013 at the Tumor and Skin Surgery Outpatient Clinic, in National Central General dr. Cipto Mangunkusumo National Hospital.⁴

Clinical manifestations of lymphangioma may present as verrucous papules and fragile translucent vesicles filled with clear fluid. It may be asymptomatic or accompanied by complaints of pain, itchy, and burning sensation.⁵ Diagnosis is usually made based on clinical features supported by histopathological examination.¹⁻³ The primary treatment is eliminating the cause of lymph vessel obstruction. Treatment modalities include electrosurgery, cryosurgery, CO₂ laser and surgical excision.² Vulvar lymphangioma, when left untreated, may cause complications. The most common complication of lymphangioma is cellulitis. Recurrence following excision procedure makes the disease difficult to cure.¹ In this article,

we reported two cases of acquired vulvar lymphangioma with different etiologies that came to our institution in January 2014.

Case illustration

Case 1. A 43-year-old female came with chief complaints of fragile vesicles in the genital area and had non-odorous clear discharge or oozing since four years prior to her first visit. She was diagnosed with cervical cancer ten years ago and had 25 radiations within two months, following a surgery. She had been declared cancer-free. She complained of pain and discomfort when having sexual intercourse. Physical examination revealed verrucous papules with skin-tone color and multiple discrete lenticular vesicles containing serous fluid on the major labia accompanied with vulvar edema. There was a bilateral lymphedema of the lower extremities. No enlarged inguinal lymph nodes was found (figure 1(A) and 1 (B)). She was diagnosed with condyloma acuminata and treated with 50% trichloroacetic acid weekly for one month but showed no response.

Skin biopsy was done on her third visit. The histopathological result demonstrated dilatation of several lymph vessels in the dermis (figure 1(C)). Treatment was done using repeated electrosurgery on the skin lesion.

Case 2 A 44-year-old female came with complaints of vesicles containing fluid in the genital area, which increasing in number since three years before her first visit to our clinic. There was a symptom of pruritus when the vesicles were ruptures, producing oozing non-odorous clear fluid. History of vesicles oozing pus and recurrent swelling on the genital area were

denied. She had a history of an enlarged lower abdomen for 15 years.

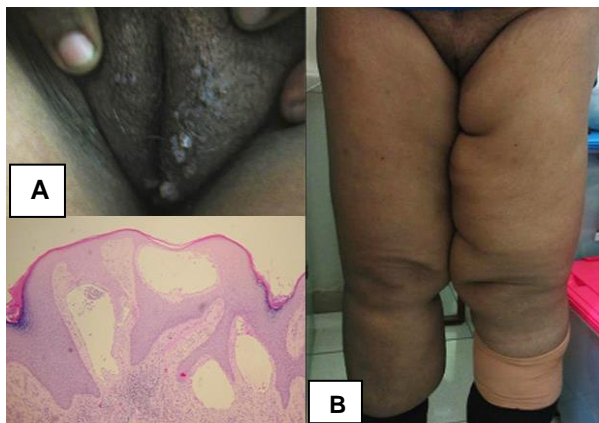

Figure 1. Skin lesions and histopathology pictures of case 1. Multiple discrete verrucous papules and vesicles, lenticular in size on the labia majora (A) accompanied by bilateral lower extremity lymphedema (B). Histopathologic features with hematoxylin and eosin staining (magnification, x10) showing multiple dilated lymphatic vessels of the dermis (C).

On physical examination, there were multiple vesicles containing serous fluid accompanied by vulvar edema.

On the lower abdomen region, there was a solitary hypotrophic scar, which she said had been there for 20 years (figure 2 (A)). An abdominal USG revealed an enlarged inguinal lymph nodes. No abnormality of other viscera was observed. The histopathological features showed multiple dilatations of superficial lymph vessels in the dermis containing lymph fluid (figure 2(B)). Treatment was done using repeated electro-surgery on the skin lesion.

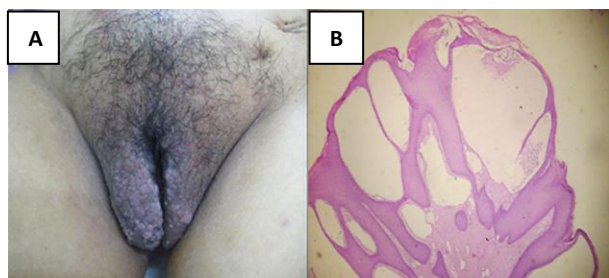


Figure 2. Skin lesions and histopathology pictures of case 2. Multiple vesicles containing clear liquid with edema of the vulva (A). Histopathologic features with hematoxylin and

eosin staining (magnification, x10) showing multiple dilated lymph vessels of superficial dermis (B).

Discussion

Lymphangioma is one of the vascular tumors that is usually congenital due to malformation of lymphatic vessels. One of the most common forms is lymphangioma circumscriptum that may occur in adults and secondary due to obstruction of lymph flow. Secondary lymphangioma circumscriptum in vulva area or vulvar lymphangioma may occur at various ages and manifests as a group of translucent 2-4 mm vesicles containing lymph fluid.⁶ It is different from the classic type, which has a predilection of the lesion in extremities. Most lesions are localized in dermal layer, but it may also penetrate to deeper layer of the skin.⁵

Acquired vulvar lymphangioma may be asymptomatic or symptomatic if the vesicles break. In our case, there was a symptom of pruritus when the vesicles ruptured, pain and discomfort when having sexual intercourse.

The underlying disorder of skin lesions in both cases was dilatation of several lymph vessels in the vulvar dermis. In case 1, the obstruction was caused by defective lymph vessel following radiation and surgery for cervical cancer. Enlarged inguinal lymph nodes in the second case produced increased pressure in the lymph vessels that might lead to bulging of the dermal lymph tract and development of vesicles. In case 2, we suspected a history of scrofuloderma since we found a hypotrophic abdominal scar. However, the infection could not be confirmed as the patient was lost to follow-up.

Several treatment modalities to eliminate the lesion are expected to provide satisfactory cosmetic result, and to prevent recurrence and infection.¹⁻² The treatment of choice is surgical excision with a high successful rate. Unlike other cases that have been reported, treatment for our both cases utilized electro-surgery. It appeared to have good responses; however, recurrences must be observe considering that the etiology of obstruction had not been managed.² It is important to suspect acquired vulvar lymphangioma for any skin lesion of papules and vesicles in vulvar region, which shows no improvement to treatment for genital wart.

References

1. Fatani MI, Bitar M, Al Afif KA, Baltow B, Baghdadi. Lymphangioma circumscriptum of the vulva mimicking genital wart: A case report. *J Saudi Soc Dermatol Dermatol Surg.* 2013;17:29-31.
2. Hamida MB, Baccouche D, El Fekih N, Fazaa B, Kamoun R. Lymphangiectasia of the vulva, treatment with CO₂ laser. *Indian J Dermatol Venereol Leprol.* 2012;78:122
3. Gnanaraj P, Revathy V, Venugopal V, Tamilchelvan D, Rajagopalan V. Secondary lymphangioma of vulva: A report of two cases. *Indian J Dermatol.* 2012;57:149-51
4. Morbidity reports. Tumor and Skin Surgery Division. Department of Dermatovenereology [unpublished data]. Jakarta: dr. Cipto Mangunkusumo; 2014
5. Chattranukulchai P, Satitthummanid S, Puwanant S, Boonyaratavej S. Lymphangioma circumscriptum of the vulva. *BMJ Case Rep.* 2013
6. Yu JTHT, Yau KC. Lymphangioma circumscriptum of the skin. *Hong Kong J.Dermatol Venereol.* 2006;14:129-33.